

See discussions, stats, and author profiles for this publication at: <https://www.researchgate.net/publication/235604787>

# Endoscopic Interlaminar Management of Lumbar Disc Disease

Article in *Journal of Neurological Surgery. Part A: Central European Neurosurgery* · March 2013

DOI: 10.1055/s-0032-1333127 · Source: PubMed

CITATIONS

45

READS

390

5 authors, including:



**YR Yadav**

Netaji Subhash Chandra Bose medical college and Hospital Jabalpur

388 PUBLICATIONS 5,243 CITATIONS

[SEE PROFILE](#)



**Vijay Parihar**

Netaji Subhash Chandra Bose Medical College, Jabalpur

188 PUBLICATIONS 2,063 CITATIONS

[SEE PROFILE](#)



**Pushpraj Bhatele**

MRI Centre, Govt Medical College

18 PUBLICATIONS 390 CITATIONS

[SEE PROFILE](#)

Some of the authors of this publication are also working on these related projects:



NeuroEndoscopy Book [View project](#)



Microsurgical training [View project](#)

# Endoscopic Interlaminar Management of Lumbar Disc Disease

Yad Ram Yadav<sup>1</sup> Vijay Parihar<sup>1</sup> Hemant Namdev<sup>1</sup> Moneet Agarwal<sup>1</sup> Pushp Raj Bhatele<sup>2</sup>

<sup>1</sup>Department of Neurosurgery, NSCB Medical College and Hospital, Jabalpur, MP, India

<sup>2</sup>Department of Radiodiagnosis, NSCB Medical College, Jabalpur, Jabalpur, MP, India

**Address for correspondence** Yad Ram Yadav, MCh, Department of Neurosurgery, NSCB Medical College and Hospital, 105 Nehru Nagar Opposite Medical College, Jabalpur MP 482003, India (e-mail: yadavyr@yahoo.co.in).

J Neurol Surg A 2013;74:77–81.

## Abstract

**Introduction** The role of surgery by minimally invasive techniques for lumbar disc disease remains unclear in the Cochrane review. There are reports of significant advantages of endoscopy over open or microdiscectomy techniques, such as better visualization of the lesion, smaller incision sizes with lower short-term morbidity, reduced hospital stay, and better education.

**Materials and Methods** Four hundred consecutive lumbar disc herniation patients underwent endoscopic interlaminar lumbar discectomy from January 2006 to December 2010 by single surgeon by Destandu system (Karl Storz, Germany). Single-level and double-level disc with unilateral or bilateral symptoms (including central, sequestered, or migrated disc) were included. Visual analog scale (VAS) scores for back pain and leg pain and MacNab criteria were recorded pre- and postoperatively.

**Results** The mean VAS score before surgery was 7.9 as compared with a 1.5 score 3 months after surgery. Postoperative VAS scores were significantly better in 90% of cases. Overall, 91% of patients had good-to-excellent results according to MacNab criteria. Accidental intraoperative single-facet injury, minor dural tear, recurrence, postoperative discitis, and persistent paresthesia were seen in 3, 7, 2, 2, and 1 patients, respectively. The mean follow-up was 24 months (range 10 months to 5 years).

**Conclusions** Endoscopic interlaminar technique (ILT) was a safe and effective alternative procedure for lumbar disc disease. This was associated with some complications, especially in the initial learning curve. Once the practitioner is over the learning curve and has acquired expertise, this procedure was safe and effective.

## Keywords

- ▶ lumbar disc herniation
- ▶ spinal endoscopy
- ▶ percutaneous lumbar disc decompression
- ▶ endoscopic lumbar discectomy

## Introduction

Lumbar disc diseases are quite common. Surgical discectomy for carefully selected patients with sciatica due to lumbar disc prolapse provides faster relief from the acute attack than conservative management.<sup>1</sup> Removal of a herniated disc using the operative microscope was first performed by Yasargil in 1977. It has been, and still is, considered the “gold standard” of surgical treatment for lumbar disc herniation and is the method used by the vast majority of spine surgeons.<sup>2</sup>

The role of surgery by minimally invasive techniques for lumbar disc disease remains unclear in the Cochrane review.<sup>1</sup> Neuroendoscopy has grown rapidly in the past 25 years as a therapeutic modality for treating a variety of brain and spinal disorders.<sup>3–5</sup> There are reports of significant advantages of endoscopy over open or microdiscectomy techniques, such as better visualization of the lesion, smaller incision sizes with lower short-term morbidity, and reduced hospital stay. In addition, spinal endoscopy allows observers and operating

received

February 20, 2012

accepted after revision

August 23, 2012

published online

February 12, 2013

© 2013 Georg Thieme Verlag KG  
Stuttgart · New York

DOI <http://dx.doi.org/10.1055/s-0032-1333127>.  
ISSN 2193-6315.

room staff to be more involved and, thus, is better for education. On the other hand, spinal endoscopy carries additional risks, and the surgeon must always be prepared to convert to an open procedure. The learning curve for spinal endoscopy is steep. Nevertheless, with training and experience, the surgeon can achieve better outcomes, reduced morbidity, and better cosmetic results. As technology evolves and more experience is obtained, neuroendoscopy will likely achieve further roles in spine surgery.<sup>4</sup> The aim of this article is to report our experience of endoscopic interlaminar technique (ILT) in lumbar disc diseases.

## Materials and Methods

Four hundred consecutive patients with lumbar disc herniation underwent endoscopic interlaminar discectomy from January 2006 to December 2010 by single surgeon. Indications for surgery were progressive neurologic deficit during observation and persistent bothersome sciatic pain despite conservative management for 12 weeks. All patients, except six with severe pain not responding to conservative treatment, were given a trial of medical therapy for at least 12 weeks. All six cases had large disc herniation and underwent surgery 3 to 5 days after the start of acute pain. Epidural or root block injection treatment and ozone treatment was also performed from other institutions in 20 and 40 patients, respectively, along with conservative management before surgery. Conservative management included bed rest, anti-inflammatory agents (steroidal and/or non-steroidal) with analgesics, and muscle relaxants. Age of the patients ranged from 19 to 65 years (average 37 years). In the beginning of the study, patients with a single nerve root lesion underwent surgery. After the initial 50 cases, single- and double-level disc with unilateral or bilateral symptoms including central, sequestered, or migrated disc were also included. Visual analog scale (VAS) scores for back pain and leg pain were recorded preoperatively and at 3, 6, and 12 months postoperatively. Patients rated their pain on the VAS from 0 (no pain) to 10 (unbearable severe pain). MacNab criteria were measured as follows: excellent (without pain or restriction of movement; patient able to work normally), good (occasional pain; patient able to work normally), fair (slight progress), and poor (no progress). All patients had preoperative magnetic resonance imaging (MRI). Postoperative MRI was performed when a patient continued to have symptoms. All patients were operated on by a single surgeon with the Destandu system (Karl Storz, Germany). Postoperatively, all patients were mobilized as soon as the pain subsided and were discharged 24 to 48 hours postsurgery. The patients files were evaluated for technical problems, complications, and overall results by MacNab criteria and VAS score. Patients were followed up at 2 and 6 weeks, 3, 6, and 12 months.

## Endoscopic Interlaminar Technique

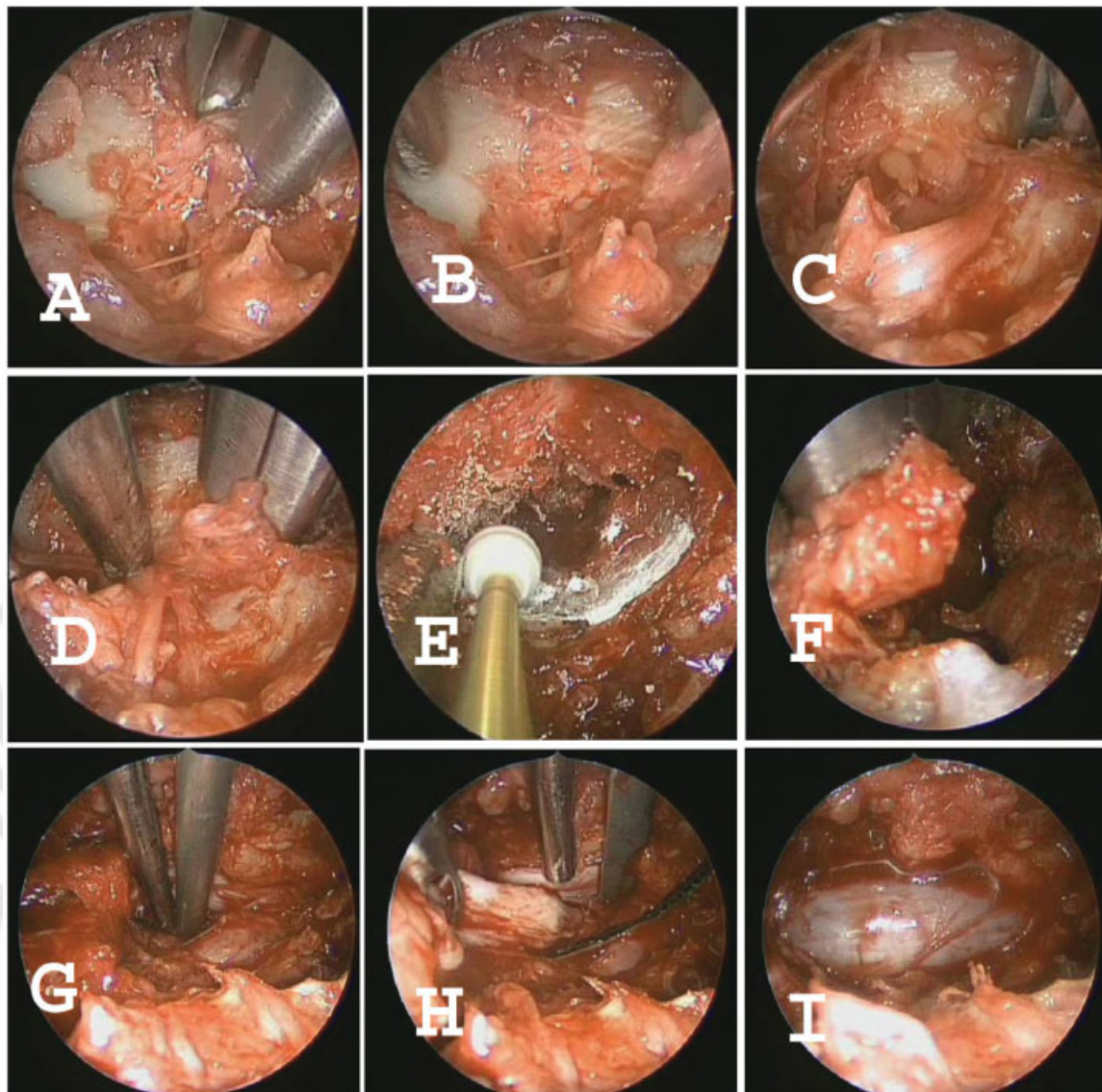
Surgery was performed in prone position on a radiolucent table under general anesthesia using a full endoscopic

technique. A microscope was not used. Destandu technique was performed using zero-degree scope (4 mm diameter and 18 cm long). The skin incision was made after confirming the level under image guidance using a C arm. A 1.5-cm skin incision was made ~1 to 1.5 cm away from midline. Fascia was cut just lateral to midline. Surgical access was created utilizing dilatation technology using stout scissors and an operating sheath. The operating sheath was directed toward the desired ligamentum flavum and lamina. Soft tissue on the lamina, facet joint, and ligamentum flavum were removed. Burrs and rongeurs were used for resection of the bone. The part of superior and inferior lamina along with the medial facet was removed (► Fig. 1). Ligamentum flavum was removed in all the cases, though it can be preserved depending on pathology and surgeons experience.<sup>6</sup>

Part of the offending disc was removed. Two-level pathologies could be addressed by moving and angulating the sheath by the same incision. Removal of opposite-side ligamentum flavum and osteophytes of the opposite facet could be done. We do not use any radiofrequency probe in our endoscopic technique. No additional costs arose aside from that for the routine micro-instruments used in other spinal and cranial endoscopic surgery. The risk of dural tear was increased when dealing with opposite-side pathology, spinal canal stenosis, central disc, and multiple levels.<sup>7,8</sup> Minor dural punctures were managed by application of a medical absorbable gelatin sponge (AbGel, Shri Gopal Krishna Labs Pvt. Ltd., Mumbai, India) on the dura while significant dural tears were treated using fat and fibrin glue.

## Results

A prospective study of 400 surgical cases of endoscopic interlaminar discectomy was performed. The mean VAS score immediately before surgery was 7.9, while it was 1.5 3 months after surgery. VAS scores for back pain and leg pain revealed statistically significant improvement in 90% of cases when compared with preoperative values. Overall, 91% of patients had good-to-excellent results according to MacNab criteria. Poor results were seen in 2% of cases. Motor weakness was observed in 17 patients preoperatively, and all of them had some recovery at follow-up. Accidental intraoperative single-facet injury occurred in 3 initial cases. Minor dural punctures occurred in 7 cases. The average operative time was 75 minutes (range 45 to 180 minutes). The average operating time was 135 minutes for the first 25 cases, 120 minutes for cases 26 through 50, and 68 minutes for the last 350 cases. There were 70 two-level cases. The average operative time in the last 280 single-level patients was 60 minutes, whereas it was 100 minutes for two levels. Average blood loss was 20 mL. In the initial learning curve, more time was required to remove the ligamentum flavum. Likewise, surgery for right-sided lesion was more time-consuming in the beginning. In the learning curve, there were difficulties due to handling of the scope, the reduced space available for dissection, resection of ligamentum flavum, and management of epidural bleeding. Two patients



**Fig. 1** Steps of endoscopic interlaminar technique showing removal of soft tissue from lamina (A), lamina in view (B), part of lamina being removed by Kerrison punch (C, D) and burr (E), ligamentum flavum being removed (F), trephine being used for perforation in the bulging disc (G), disc material being removed (H), thecal sac after bilateral decompression (I).

had recurrence and were underwent reoperation 3 and 6 months after first surgery. Two patients had postoperative discitis and both were managed conservatively. One patient had root damage and persistent paresthesia at 2-year follow-up. On analyzing the initial 50 cases, we found that most of the complications (dural tear [6 cases], facet injury [2 cases], root injury [1 case], and conversion into open surgery [1 case]) were seen in the initial learning curve. Conversion to open surgery was required in one patient that had root protrusion after dural tear in initial learning curve. Accidental intraoperative single-facet injury, root injury, and minor dural tear occurred in 1, 1, and 4 cases, respectively, in the initial 25 cases. Facet injury and minor dural tears were seen in 1 and 2 cases, respectively, in cases 26 to 50, whereas there was only one dural tear and no facet or root injury in the last 350 cases. The mean follow-up was 24 months (range 10 months to 5 years).

## Discussion

Endoscopic procedures are increasingly used for the management of brain and spine pathologies. Systematic review using the Cochrane Collaboration guidelines including all randomized or “quasi-randomized” clinical trials comparing classic open, microsurgical, and endoscopic lumbar discectomies using a posterior approach found the same long-term clinical outcome,<sup>1</sup> but results in terms of blood loss, systemic repercussions, and duration of hospital stay was superior in microsurgical and endoscopic techniques as compared with the classic open technique for the treatment of single-level lumbar disc herniations.<sup>9</sup>

VAS scores for back pain and leg pain revealed statistically significant improvement in 90% cases and over 90% had good-to-excellent results according to Macnab criteria in our series. Preoperative VAS score in our series was comparatively high.

This could be a reflection of the existing misperceptions and fear of poor results of lumbar disc surgery among patients and even amongst general practitioners in this part of the world. Most of our patients avoid surgery, accepting it only as a last option when nothing else works. This could explain comparatively high preoperative VAS score due to advanced stage of the disease. There may be some psychological element also. Similar results of over 90% good to excellent improvement, with smaller incision, less tissue trauma, and quicker recovery, were reported by other authors.<sup>10–12</sup> The 10-year long-term clinical outcome of microendoscopic discectomy in a series by Wang et al<sup>12</sup> was better than those of the traditional discectomy procedure. We also agree that almost similar results can be obtained with microscopic technique by an experienced microscopic surgeon. In our study, the viewing angle and the total area of the exposure—especially of the opposite side—was better in endoscopic surgery as compared to microscopic technique in our experience. There is also some advantage in treating two-level pathologies in terms of small incision size in endoscopic technique.

Complications such as dural tear, facet injury, root injury, conversion into open surgery, and discitis were seen in our series, but the incidence was acceptable. These complications were more in the initial learning curve. The operating time in the beginning of the learning curve was higher compared with the later part of the study when sufficient experience was gained. The average operative time in the last 280 single-level patients was 60 minutes, which is comparable to the microscopic technique. Obtaining microsurgical experience, attending workshops, and selecting suitable patients can help shorten the learning curve and decrease complications.<sup>13</sup> The complications of ILT, especially dural tears, remain a concern during the learning stage.<sup>14,15</sup> Once the learning curve was over and expertise was acquired, the procedure is safe and effective.<sup>16</sup> Similar observations of reduced back pain and fewer complications with early rehabilitation were reported in ILT technique compared with microdiscectomy by other authors.<sup>17</sup> Endoscopic ILT was found to be less traumatic than open surgery as seen in electromyography (EMG) activity.<sup>18</sup> The minimally invasive nature of the procedure was further supported by lower systemic cytokine responses (as markers of operative tissue trauma) as compared with what was observed in the open procedure.<sup>19</sup> On the other hand, the postoperative MRI changes on the nerve roots, cauda equine, and entry tract were similar in the endoscopic procedure and open surgery in another study.<sup>20</sup>

We operated on single-level unilateral disc symptoms in the beginning of our study. We started doing two levels with bilateral symptoms after having gained sufficient experience (50 cases). There are reports of use of ILT in migrated disc,<sup>21,22</sup> recurrent disc,<sup>23–25</sup> lumbar canal stenosis and lateral recess stenosis,<sup>7,8,26,27</sup> calcified disc,<sup>28</sup> and multiple-level and bilateral lesions.<sup>29</sup> Disc at L5–S1, intracanalicular migrated, calcified disc, lumbar canal stenosis, lateral recess stenosis, multiple-level, and bilateral compressions can be better approached by ILT than by transforaminal technique (TFT). In addition, most spinal surgeons are more familiar with ILT than with TFT. Endoscopic ILT can be safely done under

general and local anesthesia, and in uncooperative and anxious patients. The chances of root injury increases in general anesthesia in TFT and therefore TFT should be only done in local anesthesia.

Endoscopic ILT is more invasive than TFT. Removal of the lower part of the superior lamina, the ligamentum flavum, and the medial part of the facet joint is required in ILT, whereas these structures are not removed in TFT. Complications such as perforations of the dura, pseudomeningocele formation, cerebrospinal fluid fistula, and meningitis were more common in ILT, especially in the initial learning curve.<sup>14,15,30</sup> Endoscopic interlaminar discectomy has advantages like better illumination, magnification, visualization, minimal bone resection, minimal epidural fibrosis, less postoperative pain, better cosmetic results, shorter hospitalization, early mobilization, and shorter recovery, but this procedure has a longer learning curve and the operative time is usually longer than with open procedures in the initial experience. Two-dimensional vision of endoscopic technique may cause loss of depth perception.<sup>31</sup>

## Conclusions

Endoscopic ILT was a safe and effective alternative procedure for lumbar disc disease. This was associated with some complications, especially in the initial learning curve. Once the surgeon is over the learning curve and has developed expertise, this procedure is safe and effective.

## Conflict of Interest

None

## References

- Gibson JN, Waddell G. Surgical interventions for lumbar disc prolapse: updated Cochrane Review. *Spine* 2007;32:1735–1747
- Postacchini F, Postacchini R. Operative management of lumbar disc herniation: the evolution of knowledge and surgical techniques in the last century. *Acta Neurochir Suppl (Wien)* 2011;108:17–21
- Yadav YR, Yadav S, Sherekar S, Parihar V. A new minimally invasive tubular brain retractor system for surgery of deep intracerebral hematoma. *Neurol India* 2011;59:74–77
- Baron EM, Levene HB, Heller JE, Jallo JI, Loftus CM, Dominique DA. Neuroendoscopy for spinal disorders: a brief review. *Neurosurg Focus* 2005;19:E5
- Yadav YR, Parihar V, Agarwal M, Sherekar S, Bhatele P. Endoscopic vascular decompression of the trigeminal nerve. *Minim Invasive Neurosurg* 2011;54:110–114
- Zhou Y, Wang J, Chu TW, et al. [The clinical comparison of microendoscopic lumbar discectomy with and without preservation of the ligamentum flavum]. *Zhonghua Wai Ke Za Zhi* 2005;43:1321–1324
- Wada K, Sairyo K, Sakai T, Yasui N. Minimally invasive endoscopic bilateral decompression with a unilateral approach (endo-BiDUA) for elderly patients with lumbar spinal canal stenosis. *Minim Invasive Neurosurg* 2010;53:65–68
- Ikuta K, Tono O, Tanaka T, et al. Surgical complications of microendoscopic procedures for lumbar spinal stenosis. *Minim Invasive Neurosurg* 2007;50:145–149

- 9 Gotfryd A, Avanzi O. A systematic review of randomised clinical trials using posterior discectomy to treat lumbar disc herniations. *Int Orthop* 2009;33:11–17
- 10 Li SH, Li HZ, Zhao JR. [Clinical comparison between micro-endoscopic discectomy (MED) and open discectomy for treatment of lumbar disc herniation]. *Zhongguo Gu Shang* 2008;21:349–351
- 11 Righesso O, Falavigna A, Avanzi O. Comparison of open discectomy with microendoscopic discectomy in lumbar disc herniations: results of a randomized controlled trial. *Neurosurgery* 2007;61:545–549, discussion 549
- 12 Wang M, Zhou Y, Wang J, Zhang Z, Li C. A 10-year follow-up study on long-term clinical outcomes of lumbar microendoscopic discectomy. *J Neurol Surg A Cent Eur Neurosurg* 2012;73:195–198
- 13 Wang B, Lü G, Patel AA, Ren P, Cheng I. An evaluation of the learning curve for a complex surgical technique: the full endoscopic interlaminar approach for lumbar disc herniations. *Spine J* 2011;11:122–130
- 14 Chang SS, Fu TS, Liang YC, et al. Results of microendoscopic discectomy performed in the 26 cases with a minimum 3 years follow-up. *Chang Gung Med J* 2009;32:89–97
- 15 Teli M, Lovi A, Brayda-Bruno M, et al. Higher risk of dural tears and recurrent herniation with lumbar micro-endoscopic discectomy. *Eur Spine J* 2010;19:443–450
- 16 Jhala A, Mistry M. Endoscopic lumbar discectomy: Experience of first 100 cases. *Indian J Orthop* 2010;44:184–190
- 17 Ruetten S, Komp M, Merk H, Godolias G. Full-endoscopic interlaminar and transforaminal lumbar discectomy versus conventional microsurgical technique: a prospective, randomized, controlled study. *Spine* 2008;33:931–939
- 18 Schick U, Döhnert J, Richter A, König A, Vitzthum HE. Microendoscopic lumbar discectomy versus open surgery: an intraoperative EMG study. *Eur Spine J* 2002;11:20–26
- 19 Huang TJ, Hsu RW, Li YY, Cheng CC. Less systemic cytokine response in patients following microendoscopic versus open lumbar discectomy. *J Orthop Res* 2005;23:406–411
- 20 Muramatsu K, Hachiya Y, Morita C. Postoperative magnetic resonance imaging of lumbar disc herniation: comparison of microendoscopic discectomy and Love's method. *Spine* 2001;26:1599–1605
- 21 Ruetten S, Komp M, Godolias G. A New full-endoscopic technique for the interlaminar operation of lumbar disc herniations using 6-mm endoscopes: prospective 2-year results of 331 patients. *Minim Invasive Neurosurg* 2006;49:80–87
- 22 Choi G, Prada N, Modi HN, Vasavada NB, Kim JS, Lee SH. Percutaneous endoscopic lumbar herniectomy for high-grade down-migrated L4-L5 disc through an L5-S1 interlaminar approach: a technical note. *Minim Invasive Neurosurg* 2010;53:147–152
- 23 Zhou Y, Wang J, Chu TW, et al. [Micro-endoscopic strategies and options for recurrent lumbar disc herniation]. *Zhonghua Wai Ke Za Zhi* 2008;46:1475–1479
- 24 Smith JS, Ogden AT, Shafiqzadeh S, Fessler RG. Clinical outcomes after microendoscopic discectomy for recurrent lumbar disc herniation. *J Spinal Disord Tech* 2010;23:30–34
- 25 Ruetten S, Komp M, Merk H, Godolias G. Recurrent lumbar disc herniation after conventional discectomy: a prospective, randomized study comparing full-endoscopic interlaminar and transforaminal versus microsurgical revision. *J Spinal Disord Tech* 2009;22:122–129
- 26 Sairyo K, Sakai T, Higashino K, Inoue M, Yasui N, Dezawa A. Complications of endoscopic lumbar decompression surgery. *Minim Invasive Neurosurg* 2010;53:175–178
- 27 Zhai XJ, Bi DW, Fu H, Zu G. [Treatment of lumbar disc herniation with lateral recess stenosis by microendoscopic discectomy]. *Zhongguo Gu Shang* 2008;21:120–121
- 28 Matsumoto M, Watanabe K, Tuji T, et al. Microendoscopic discectomy for lumbar disc herniation with bony fragment due to apophyseal separation. *Minim Invasive Neurosurg* 2007;50:335–339
- 29 Zhang XB. [Endoscopic surgical procedures for the treatment of multi-segment lumbar intervertebral disc herniation with posterior approach]. *Zhongguo Gu Shang* 2009;22:295–296
- 30 Liu WG, Wu XT, Min J, et al. [Long-term outcomes of percutaneous lumbar discectomy and microendoscopic discectomy for lumbar disc herniation]. *Zhonghua Yi Xue Za Zhi* 2009;89:750–753
- 31 Oztürk C, Tezer M, Aydoğan M, Sarier M, Hamzaoglu A. Posterior endoscopic discectomy for the treatment of lumbar disc herniation. *Acta Orthop Belg* 2006;72:347–352