

ISAKOS

ISAKOS NEWSLETTER 2023 • VOLUME I

Current Concepts on Arthroscopy, Knee Surgery & Orthopaedic Sports Medicine



WELCOME!



ISAKOS
CONGRESS
2023



Boston
Massachusetts
June 18–June 21



PG 38

TITLE IX LEGISLATION:
GENDER DIVERSITY TASK FORCE



- INSIDE 16** ANKLE SYNDESMOSIS
LIGAMENT INSTABILITY
- 20** ADDRESSING FAILED SURGICAL
RECONSTRUCTION OF THE MEDIAL
SIDE OF THE KNEE
- 24** OSTEO-CORE-PLASTY
- 30** VIRTUAL TRAINING AND THE REALITY
OF TAKING A BREAK AS A SURGEON
- 40** AANA/ISAKOS KNEE & SHOULDER
ARTHROSCOPY COURSE RECAP

Addressing Failed Surgical Reconstruction of the Medial Side of the Knee: A Case Illustration



Rajkumar S. Amaravathi, DNB, FRCS
St. Johns Medical College
Bangalore, Karnataka, INDIA



Rinju Krishnan, MS (Orth), DNB
St. Johns Medical College
Bangalore, Karnataka, INDIA



Rahul Shah, MS (Orth), D. Orth
St. Johns Medical College
Bangalore, Karnataka, INDIA



Sunil Lakshmipura Krishnamurthy, MS (Orth), DNB
St. Johns Medical College
Bangalore, Karnataka, INDIA



Abhey Wasdev, MS
St. Johns Medical College
Bangalore, Karnataka, INDIA



Jaya Vaishnavi Lal, MBBS
St. Johns Medical College
Bangalore, Karnataka, INDIA

Introduction

The medial collateral ligament (MCL) is the main static stabilizer of the medial side of the knee for valgus stress, rotational pressures, and anterior translational forces. The superficial medial collateral ligament (sMCL) has been reported to be the most commonly injured knee ligament, accounting for 42% of ligamentous knee injuries.^{1,2} Most of these injuries can be treated conservatively with good clinical results. However, surgical reconstruction is required for the treatment of major instability, chronic injuries, multi-ligamentous injuries, or MCL avulsion on the femoral or tibial side.

Anatomically imprecise graft placement and suboptimal graft-fixation methods can lead to an over-constrained knee, residual instability, graft loosening, or implant failure, which can present challenges during subsequent corrective surgery.^{2,3,4}

Anatomy and Biomechanics of the MCL

The medial side of the knee has three important structures: (1) the superficial medial collateral ligament (sMCL), (2) the deep medial collateral ligament (dMCL), and (3) the posterior oblique ligament (POL). The sMCL is the largest and strongest of the three, is rather flat, and has broad insertion sites on both femoral and tibial sides. The dMCL is an inverted fan-shaped structure passing from its small femoral attachment to a wide tibial attachment. Laprade et al^{1,2} described the attachments of the sMCL, dMCL, and POL. The femoral attachment of the sMCL is 3.2 mm proximal and 4.8 mm posterior to the centre of the medial epicondyle. The two tibial attachments of the sMCL, proximal and distal, are approximately 12.2 mm and 61.2 mm distal to the joint line, respectively. The femoral attachment of the POL is 7.7 mm distal and 6.4 mm posterior to the adductor tubercle (AT) and is 1.4 mm distal and 2.9 mm anterior to the gastrocnemius tubercle (GT). The tibial attachment of the POL is just anterior to the direct arm of attachment of the semimembranosus tendon. Biomechanical studies have suggested that the sMCL is the major restraint to valgus motion at all angles and external tibial rotation, especially at 90° of knee flexion. The POL is an important restraint to internal tibial rotation and valgus rotation in full extension. Recent studies have highlighted the relevance of the dMCL in controlling external tibial rotation.

Presentation and Diagnosis

Injury to the MCL is due to excessive stress on the medial side of the knee, causing the fibers within the MCL to stretch out. Common reasons include valgus forces acting on the knee during sports activity or in road traffic accidents. Patients present with pain directly over the ligament, swelling, and inflammation over the medial part of the knee. In severe injuries, patients may feel the knee “give out” or buckle. Clinically, there is medial joint line tenderness along with tenderness over the MCL attachments. Valgus stress testing is done at 0° and 20° of knee flexion.

During the test, the medial-side opening of the knee is checked and classified into 3 grades based on severity according to the system of Hughston et al. The anterior rotatory drawer test is another diagnostic tool that helps in assessing posterior medial rotatory instability.

Management

Standard radiographs of the knee and valgus comparative stress radiographs at 0° and 20° of knee flexion are taken. At 20° of flexion, a difference of 3.2 mm indicates an isolated lesion of the sMCL and a difference of >9.8 mm indicates involvement of the whole posteromedial corner. MRI of the knee is an important tool in diagnosing MCL injuries. In patients with a chronic medial-side knee injury, it is advisable to obtain a standing scannogram of both lower limbs to check for any malalignment.

There is a broad consensus that the majority of isolated grade-I and II MCL injuries heal with rehabilitation alone. Most patients return to sports at 3 months, with excellent long-term patient-reported outcomes. Although grade-III injuries also may heal without surgery, some patients remain symptomatic following conservative treatment, necessitating reconstruction. Combined sMCL and POL injuries may be associated with an increased incidence of failure to respond to nonoperative treatment and may result in persistent MCL instability. Currently available surgical options include anatomic medial knee reconstruction (as described by Laprade et al.), the use of a single femoral tunnel combined with two tibial tunnels (as described by Lind et al.), repair of MCL avulsion with or without augmentation, MCL reconstruction with augmentation (fibre tapes/suture anchors), and MCL reconstruction with the flat tendon (as described by Abermann et al.⁴).

Why Does Reconstruction Fail?

Patient-Related Factors

Factors such as age, obesity (BMI >30), smoking, the activity status of the patient, generalized ligament laxity, and noncompliance with the rehabilitation protocol can contribute to the failure of surgical reconstruction. Early joint motion is crucial for maintaining mechanical properties and prevents the disorganization of collagen fibrils. The ability to initiate early postoperative mobilization allows for the return of knee function while minimizing the development of arthrofibrosis.

Diagnosis-Related Factors

Failure to diagnose posteromedial rotatory instability or failure to recognize the malalignment of the extremity may contribute to inadequate addressing of the problem and eventually may lead to failure.

Tunnel-Related Factors

Incorrect tunnel placement leads to a non-isometric tunnel, which will contribute to abnormal graft tensioning, leading to persistent laxity or overconstraint.

Graft-Related Factors

Soft-tissue grafts may stretch out over a period of time. Smaller-diameter soft-tissue grafts also may not give the desired results. It is difficult to reproduce the native flat-shaped MCL. Hence, the use of conventional tubular grafts probably would result in point-to-point fixation over a wide footprint and may lead to failure. Fixation of the graft with screw fixation or suspensory fixation is superior to the use of bone staples.

Tips and Tricks to Enhance the Outcome

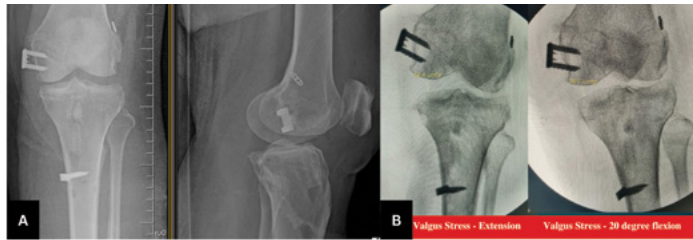Studies have suggested that using a flat tendon as a graft is advantageous as compared with conventional tubular grafts. Rerouting the graft along the native MCL would recreate the anatomy and would result in effective graft tensioning. Tendon stretch-out is a common problem with soft-tissue grafts; hence, augmenting the graft with fiber tapes or suture anchors in extra-articular procedures probably would help to maintain graft tension until ligamentization is achieved. The use of additional meniscocapsular sutures for graft augmentation is another technique. The aperture of the tunnels should be cleared of all soft tissue to enable easy passage of the graft. Secondary/accessory fixation can also be added to reinforce the construct. However, long-term follow-up is required.

Case Illustration

A 42-year-old morbidly obese female patient (BMI, 40.6) presented to the outpatient department because of difficulty with walking following an injury to the left knee that had been sustained in a road traffic accident 10 months previously. The patient had been diagnosed with a multi-ligamentous injury of the knee and had undergone reconstruction of the ACL, PCL, and medial side of the knee 1 month after the injury. Following the initial procedure, the patient was instructed to perform regular knee exercises and to walk after 2 months. At the time of presentation to our outpatient department, the patient still complained of instability in the left knee and the inability to walk. Physical examination of the left knee revealed tenderness over the medial joint line and femoral and tibial attachment of the MCL. The anterior drawer test, Lachman test, and posterior drawer test were negative. The valgus stress test was positive, with pain and medial opening when the test was performed with the knee both in complete extension and in 20° of flexion (Grade 3 on the Hughston scale).

A radiograph of the knee showed a previous ACL tunnel with an endobutton on the femoral side and bio-screw on the tibial side (Fig. 1). The PCL tunnel had bio-screws on both the femoral and tibial sides. The previous MCL graft was fixed with bone staples on both the femoral and tibial sides. Valgus stress radiographs made with the knee in 0° and 20° of flexion showed a medial-side opening of >10 mm. The patient was diagnosed with a failed MCL reconstruction and was scheduled for revision surgical reconstruction of the medial side of the knee.

Addressing Failed Surgical Reconstruction of the Medial Side of the Knee: A Case Illustration



01-A Pre-operative x-ray of the left knee – Bone staples over MCL attachments & previous tunnels for ACL and PCL.
01-B Valgus stress views showing >10 mm medial side opening.

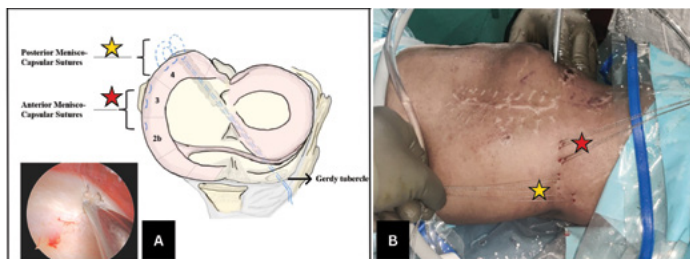
Surgical Technique

Positioning

The patient was positioned supine under anesthesia. A tourniquet was applied over the thigh. Knee range of motion between 0° to 120° was possible.

Arthroscopy

Diagnostic arthroscopy revealed vascularization of the previous ACL and PCL grafts. The medial femoral and tibial condyles showed Outerbridge Grade-1 cartilage changes. The medial compartment drive-through sign was seen. Both menisci were found to be intact. Six inside-out menisco-capsular sutures (three in Smigielski⁵ Zone 4 of the medial meniscus [posterior] and three in Smigielski⁵ Zones 2b and 3 of the medial meniscus [anterior]) were inserted with use of no. 2-0 fibre-wire (Sironix; Healthium, Peenya, Bangalore, India) for the planned augmentation of the grafts (Fig. 2).



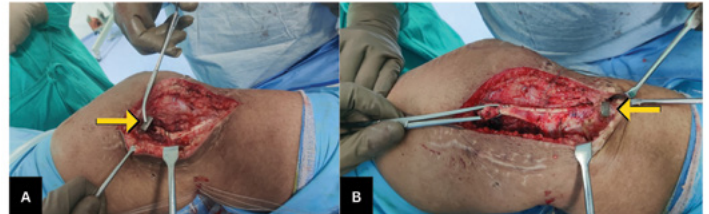02-A Inside-out Menisco-capsular sutures taken in zones 2b, 3 & 4.
02-B Inside-out Menisco-capsular sutures – anterior (★) and posterior sutures (★).

Medial-Side Exposure

On the medial side, an incision (approximately 10 cm long) was made. The soft tissue was dissected, and the previous MCL graft was exposed and was found to be lax.

The femoral-side bone staple was loose, and the femoral tunnel was found to be non-anatomical (Fig. 3-A). On the tibial side, the bone staple was holding the graft, which had become vascularized (Fig. 3-B). Hence, the tibial side was left undisturbed. The femoral bone staple was then removed and the previous lax graft was reflected to the tibial side.

We decided to revise the medial side reconstruction with a single femoral tunnel and two tibial tunnels (one each for the sMCL and the POL) along with augmentation of the grafts with menisco-capsular sutures.



03-A Previous lax ligament along with loose bone staple on the femoral side.
03-B Previous tibial side bone staple along with ligamentized graft.

Graft Preparation

A minimum graft length of at least 22 to 26 cm is required for the reconstruction of the sMCL. As the hamstrings on the ipsilateral side were already used during the primary surgery, semitendinosus and gracilis grafts were harvested from the contralateral leg. The length of the semitendinosus and gracilis grafts were 28 and 24 cm, respectively. Grafts were clubbed together to make one limb for the femoral tunnel and two limbs for the tibial tunnels. Grafts were augmented with use of fibre tapes (Sironix; Healthium, Peenya, Bangalore, India).

First, both the semitendinosus and gracilis grafts were sutured side-to-side at both ends. The graft was folded onto itself to make a shorter limb and a longer limb comprising one-third and two-thirds of the graft length, respectively. A 25-mm looped end of the graft was prepared with use of a Krackow stitch with no. 2 non-absorbable fibre-wire (Sironix; Healthium, Peenya, Bangalore, India) for the graft placement in the femoral tunnel. Similarly, a shorter limb of the graft, which was to be used for POL reconstruction, was prepared, and a length of 25 mm was marked from the end to serve as a guide for the length of the graft to be inside the POL tibial tunnel. In the same fashion, a longer limb of the graft was prepared, and a length of 25 mm was marked to be used for the tibial side of the sMCL.

Tunnel Preparation

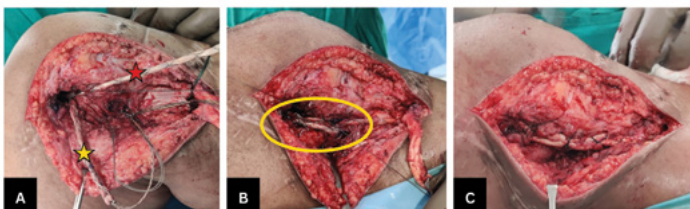Femoral tunnel. A 2.4-mm guide-pin was placed over the anatomical location of the sMCL femoral attachment (3.2 mm proximal and 4.8 mm posterior to the medial epicondyle as per Laprade et al.). The location was confirmed with fluoroscopy. The guide-pin was advanced and, with use of the appropriately sized reamer, a femoral socket measuring 7 x 25 mm was prepared.

Tibial sMCL tunnel. A 2.4-mm guide pin was placed over the anatomical location of the sMCL tibial tunnel (61.2 mm distal to the joint line as per Laprade et al.). The guide-pin was advanced and, with use of a 6-mm reamer, a tibial socket measuring 6 x 25 mm was prepared. The tibial bone staple along with the previously attached graft was left undisturbed.

Tibial POL tunnel. A 2.4-mm guide pin was placed over the anatomical location of POL (anterior to semimembranosus as per Laprade et al.), and the guide-pin was advanced and directed towards Gerdy's tubercle. With use of a 6-mm reamer, tibial socket measuring 6 x 25 mm was prepared.

Graft Insertion

The sutures of the graft were shuttled into the previously drilled tunnels, with the looped end shuttled into the femoral tunnel (Fig. 4-A). The femoral side was secured with an 8 x 25-mm bioscrew (Sironix; Healthium, Peenya, Bangalore, India). The POL (shorter limb) side of the graft along with 3 posterior menisco-capsular sutures was shuttled into the POL tibial tunnel and was secured with a 7 x 25-mm bio-screw with the knee in full extension. The sMCL (longer limb) side of the graft was passed into the tibial tunnel for the sMCL and was secured with a 7 x 25-mm bio-screw with the knee in 20° of flexion. The three anterior menisco-capsular sutures were then sutured over the sMCL graft (Fig. 4-B). The previous graft was also then sutured over to the newly reconstructed MCL, and thus augmentation of the new graft was achieved (Fig. 4-C). Accessory fixation was achieved by tying the free ends of fibre-wires of both limbs of the graft (sMCL and POL) over the anteromedial aspect of the tibia.

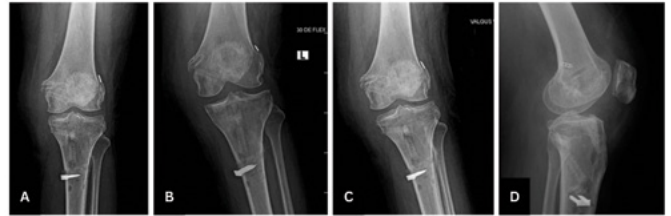

- 04-A Graft with looped end fixed inside the femoral tunnel. Short link (★) for POL along with posterior meniscocapsular sutures. Long limb (★) for sMCL. Also note augmentation of the graft with fibre tapes.
- 04-B Suturing anterior menisco-capsular sutures over the reconstructed sMCL.
- 04-C Previous graft augmented over the newly reconstructed ligament.

Postoperative Protocol and Rehabilitation

The patient was allowed up to 30° of knee flexion for the first 3 weeks and up to 60° for the next 3 weeks and was managed with non-weight-bearing mobilization for the first 6 weeks. From 6 to 9 weeks, the patient was allowed knee flexion up to 90°, along with partial weight-bearing mobilization with the knee locked in complete extension. At the time of the latest follow-up at 3 months, the patient was walking with full weight-bearing.

Knee flexion of up to 110° was achieved, with no extension lag, and valgus stress radiographs of the left knee showed no significant medial-side opening (Fig. 5).



- 05 Post-operative radiographs of the left knee at 3 months follow up.
- 05-A AP view in full extension.
- 05-B AP view with valgus stress in full extension.
- 05-C AP view with valgus stress in 20 degrees of flexion.
- 05-D Lateral view.

Summary

Reconstruction of the medial side of the knee is a challenging situation. There can be catastrophic anatomical consequences if the underlying problem is not properly diagnosed and treated. Failure of the primary procedure can cause substantial distress that can affect activities of daily living. From a surgeon's point of view, revision of a failed MCL reconstruction presents a plethora of challenges, warranting thorough planning of the procedure. Surgical intervention should be done to recreate the anatomic reconstruction of the medial side of the knee by addressing the sMCL and POL. The addition of menisco-capsular sutures to the grafts for reconstruction of the sMCL and POL can help to augment the surgical construct. The end result should be accomplished by achieving a stable knee with the resolution of laxity and instability throughout the range of motion.

References:

1. LaPrade MD, Kennedy MI, Wijdicks CA, LaPrade RF. Anatomy and biomechanics of the medial side of the knee and their surgical implications. *Sports Med Arthrosc Rev.* 2015 Jun;23(2):63-70. doi: 10.1097/JSA.000000000000054. PMID: 25932874.
2. Laprade RF, Wijdicks CA. Surgical technique: development of an anatomic medial knee reconstruction. *Clin Orthop Relat Res.* 2012 Mar;470(3):806-14. doi: 10.1007/s11999-011-2061-1. PMID: 21909850; PMCID: PMC3270176.
3. Kittl C, Robinson J, Raschke MJ, Olbrich A, Frank A, Glasbrenner J, Herbst E, Domnick C, Herbolt M. Medial collateral ligament reconstruction graft isometry is effected by femoral position more than tibial position. *Knee Surg Sports Traumatol Arthrosc.* 2021 Nov;29(11):3800-3808. doi: 10.1007/s00167-020-06420-8. Epub 2021 Jan 17. PMID: 33454831; PMCID: PMC8514388.
4. Abermann E, Wierer G, Herbolt M, Smigielski R, Fink C. MCL Reconstruction Using a Flat Tendon Graft for Anteromedial and Posteromedial Instability. *Arthrosc Tech.* 2022 Feb 8;11(3): e291-e300. doi: 10.1016/j.eats.2021.10.019. PMID: 35256966; PMCID: PMC8897492.
5. Smigielski R, Becker R, Zdanowicz U, Ciszek B. Medial meniscus anatomy-from basic science to treatment. *Knee Surg Sports Traumatol Arthrosc.* 2015 Jan;23(1):8-14. doi: 10.1007/s00167-014-3476-5. Epub 2014 Dec 24. PMID: 25536949.