

Perineal Hernia in Dogs: Which Technique Should We Use?

Arícia Gomes Sprada¹, Rafael Ricardo Huppes², João Pedro Scussel Feranti³,
Fernando Wiecheteck de Souza⁴, Lívia de Paula Coelho¹, Paola Castro Moraes¹ & Bruno Watanabe Minto¹

ABSTRACT

Background: Perineal hernia may be unilateral or bilateral and results from weakening and separation of the pelvic diaphragm muscles, favoring the abdominal viscera herniation into the perineal subcutaneous. The factors described as possible etiology of this affection are prostate hyperplasia, senile muscular atrophy, myopathy and hormonal imbalances. Several herniorrhaphy techniques are available in literature presenting different rates of success leaving the question whether there is any technique that is predominantly better than others are. This case report aims to describe five cases of perineal hernia treated with four different techniques performed by four experienced surgeons.

Cases: *Case 1. Semitendinous muscle transposition:* A 8-year-old intact male Shitzu (6 kg) was referred for the evaluation of a swelling in the right perineal region. The mass was soft and regressed into the pelvic cavity during palpation. Abdominal ultrasound and radiography were taken, which revealed perineal hernia and a mild prostate enlargement. The patient was prepared for hernia repair with semitendinous muscle transposition and orchiectomy. *Case 2. Internal obturator muscle transposition:* A 9-year-old intact male mixed breed dog (18kg) presenting a two-week long unilateral (right-side) perineal hernia. Ultrasound exam revealed a cystic prostate and adipose tissue as the hernia content. After clinical and image examination the patient was submitted to surgical repair using the internal obturator muscle transposition technique and orchiectomy. *Case 3. Internal obturator muscle transposition associated to correction of rectal sacculation:* A 12-year-old intact male mixed breed presenting swelling on the right side of the perianal region. The owner reported a 4-day long aqueous, emesis and increased volume in perineum for 6 months. During the rectal palpation, resected fecal content was present and rectal sacculation was suspected. Enema, simple abdominal radiography, contrast radiography and ultrasonography were performed. The exams showed perineal hernia with bowel content and presence of rectal sacculation. The patient was submitted to surgery in order to correct the perineal hernia and rectal sacculation, and to perform orchiectomy. *Case 4. Polypropylene mesh:* A 13-year-old intact male dachshund dog (8.6 kg) was referred to clinical examination due to a 1-year-history complaint of a mass in the right perineal area. The owner also reported rectal prolapse and stranguria noted two days prior the consultation. Ultrasound and radiography showed bladder, prostate and bowel contained in hernia sac. The patient underwent to hernia repair with polypropylene mesh and castration. *Case 5. Bovine pericardium preserved in 4% formaldehyde:* A 7-year-old intact male mixed breed dog (14 kg) was presented to clinical evaluation with swelling lateral to the anus and dyschezia. Abdominal radiography and ultrasound revealed images suggestive of perineal hernia with urinary bladder, prostate and bowel content. The patient was referred to surgery.

Discussion: Perineal herniations are commonly related to weakness of pelvic diaphragm muscles. However, the etiology involved in this process is undetermined. Success rate of perineal hernia repair techniques vary in literature. It can be speculated that local factors may influence these results, such as the surgeon ability to perform the technique or to recognize components that adversely affects the surgery. The results were considered satisfactory in all cases, which may answer the question: the better technique is the one we perform better.

Keywords: herniorrhaphy, muscle transposition, polypropylene mesh, bovine pericardium, canine.

INTRODUCTION

Perineal hernia may be unilateral or bilateral and results from weakening and separation of the pelvic diaphragm muscles, favoring the abdominal viscera herniation into the perineal subcutaneous. The factors described as possible etiology of this affection are prostate hyperplasia, senile muscular atrophy, myopathy and hormonal imbalances. Clinical signs generally are dyschezia, increased perineal volume and, in some cases, hyperemia, hyperthermia and pain in the perineal region [8]. Diagnosis is based on physical examination associated with radiography and ultrasound. Herniorrhaphy is the treatment of choice. There are several techniques described including anatomical reposition of the pelvic diaphragm with suture, internal obturator muscle transposition, superficial gluteal muscle transposition, semitendinosus muscle transposition and use of synthetic meshes or biological membranes [1]. This case report aims to describe five cases of perineal hernia treated with four different techniques performed by four experienced surgeons.

CASES

Case 1. Semitendinosus muscle transposition

A 8-year-old intact male Shitzu (6 kg) was referred for the evaluation of a swelling in the right perineal region. The mass was soft and regressed into de pelvic cavity during palpation. Clinical signs were tenesmus, hyperemia, hypertemia and local pain. Abdominal ultrasound and radiography were taken, which revealed perineal hernia and a mild prostate enlargement (5x6 cm). Complete blood count, creatinine, and alkaline phosphatase were within the parameters. The patient was prepared for hernia repair with semitendinosus muscle transposition and orchiectomy. Ceftriaxone (Rocefin®)¹ was administered intravenous 30 min before the surgery. Premedication consisted in association of midazolam (Dormonid®)² and morphine (Dimorf®)³ both intramuscular. The patient was induced with propofol (Diprivan 1%®)⁴ intravenous. General anesthesia was maintained with isoflurane (Forane®)⁵. The patient was placed in sternal recumbency and antisepsis was performed with povidone iodine (Riodine®)⁶ and 70% alcohol (Rialcool 70®)⁶.

A dorsoventral skin incision was made over the hernia and extended caudally to the knee. Subcutaneous and the hernia sac were incised to reduce the hernia. The semitendinosus muscle was identified and

dissected carefully with metzembaum. Its tendon of insertion was released and the semitendinosus muscle was dislocated and placed between the coccygeal muscle, the internal obturator, and the pelvic fascia. The muscle was sutured using a simple interrupted 2-0 polyglactine 910 (Vicryl®)⁷ (Figure 1). A Penrose drain (Dreno de Penrose Waltex®)⁸ was positioned and maintained for 3 days. The subcutaneous tissue and the skin were sutured as routinely. Postoperative medication consisted in ranitidine (Antak®)⁹ every 12 h during 12 days, cephalexin (Keforal®)¹⁰, every 12 h during 12 days, tramadol (Tramal®)¹¹ every 12 h for 5 days, dipyron (Novalgina®)¹⁰, and meloxicam (Maxicam®)¹² every 24 h for 3 days. Surgical wound cleaning was performed using 0.9% steril saline solution (Cloreto de Sódio 0,9%)¹³ twice daily during 15 days. An elizabethan collar was placed. At the 5-day post surgery, there was suture dehiscence in the proximal portion of the anus, which was treated with delayed closure 5 days after. After 15 days postoperative, skin suture were removed. Two years after the surgery the patient presents no signs of recurrence or other complication.

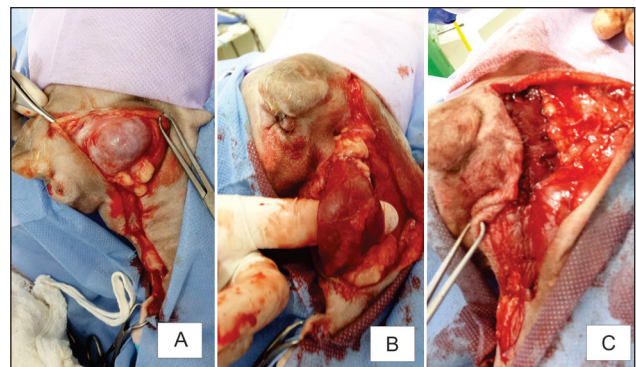


Figure 1. Sequence of the surgical procedure of the herniorrhaphy technique using the semitendinosus muscle in a dog with perineal hernia. A- Patient placed in sternal recumbency. A dorsoventral skin incision was made over the hernia to expose the hernia sac. B- The semitendinosus muscle was identified and dissected carefully with metzembaum. C- semitendinosus muscle was dislocated and placed between the coccygeal muscle, the internal obturator, and the pelvic fascia. The muscle was sutured using a simple interrupted.

Case 2. Internal obturator muscle transposition

A 9-year-old intact male mixed breed dog (18 kg) presenting unilateral (right-side) perineal hernia 2 weeks prior the attendance was referred to the veterinary hospital. Complete blood count and biochemical test (creatinine, urea and alkaline phosphatase) were within the parameters. Ultrasound exam revealed a cystic prostate and adipose tissue as the hernia content. After clinical

and image examination the patient was submitted to surgical repair using the internal obturator muscle transposition technique and orchiectomy. Ampicillin (Ampicilina[®])¹ was administered intravenous 30 min before the surgery. Premedication consisted in association of acepromazine (Acepran[®])¹⁴ and meperidine (Dolantina[®])¹⁵ intramuscular. The patient was induced with propofol (Diprivan[®])⁴ intravenous. General anesthesia was maintained with isoflurane (Forane[®])⁵. Trans-operative analgesia was achieved with continuous remifentanyl (Ultiva[®])⁹. Prescrotal orchiectomy was performed as usual. To repair the perineal hernia, a dorsoventral skin incision was made over the hernia and parallel to the anus. Subcutaneous tissue was folded and the hernia sac was identified and incised in order to relocate the herniated structures into the abdominal cavity. The internal obturator muscle was released from the ischium with the aid of a periosteal elevator. The muscle was sutured to the levator ani and coccygeous muscles with mayo mattress suture 2-0 polypropylene (Prolene[®])⁷ [Figure 2]. Subcutaneous and skin were closed as usual. Postoperative medication consisted in cephalexin (Keforal[®])¹⁰ every 12 h for 7 days, carprofen (Carpoflan[®])¹⁶ every 12 h for 5 days, tramadol (Tramal[®])¹¹ every 6 h during 3 days, dipyron (Novalgina[®])¹⁰ every 6 h for 5 days, and lactulose (Lactulona[®])¹⁷ every 12 h for 10 days. Lavage of the wound and bandage were performed twice daily with saline solution (Cloreto de Sódio 0,9%)¹³ and elizabethan collar was placed. There were no complications and 7 days after surgery the skin sutures were removed. After 1 year and 8 months of follow up, there was no recurrence.

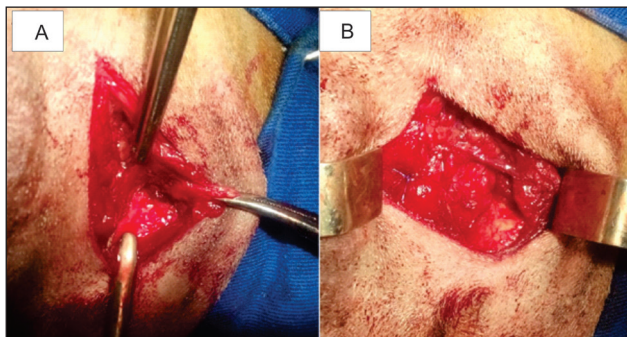


Figure 2. Herniorrhaphy technique using the obiturator muscle in a dog with perineal hernia. A- dorsoventral skin incision was made over the hernia and parallel to the anus, hernia sac was identified. B- Obiturator muscle was sutured to the levator ani and coccygeous muscles with mayo mattress suture.

Case 3. Internal obturator muscle transposition associated to correction of rectal sacculation

A 12-year-old intact male mixed breed dog was admitted at the veterinary hospital presenting swelling on the right side of the perianal region. The owner reported a 4-day long aquesia, emesis and increased volume in perineum for 6 months. Physical examination revealed a mild dehydration (4%), apathy, pain in the abdominal palpation, firm and voluminous intestinal loops. During the rectal palpation, resected fecal content was present and rectal sacculation was suspected. Enema, simple abdominal radiography, contrast radiography and ultrasonography were performed. The exams showed perineal hernia with bowel content and presence of rectal sacculation. Complete blood count (CBC) demonstrated anemia and pancytopenia [HE - 3260; LE - 4900; HB - 8.2; HT - 20.9; BAS - 00; EOS - 04; NB - 01; NS - 82; LINF - 12; MON - 01; PLAQ - 136000]. As ehrlichiosis and babesiosis is endemic in the region, doxycycline¹² (Doxifin[®]) every 24 h during 30 days and dipropionate imodocarb (Imizol[®])¹⁸ subcutaneous (second dose in 15 days) were initiated. Biochemical tests (alanine transaminase and creatinine) were normal. Mineral oil, pasty food, dipyron (Novalgina[®])¹⁰ every 6 h and ranitidine (Antak[®])⁹ were also administrated during 15 days prior the surgery when CBC was repeated presenting improvement [HE - 4110; LE - 5900; HB - 10; HT - 26.7; BAS - 00; EOS - 04; NB - 01; NS - 82; LINF - 09; MON - 01; PLAQ - 137000]. The patient was submitted to surgery in order to correct the perineal hernia and rectal sacculation, and to perform orchiectomy. After preparation of the surgical field, a lubricated syringe was inserted into the anus to rectal identification during the surgery. Skin and subcutaneous tissue were incised parallel to the anus. Perineal hernia content was reduced and maintained with the aid of a gauze. The rectal sacculation was retracted and clamped with atraumatic intestinal forceps. Wolff sutures were placed between the forceps and the rectum allowing the sacculation excision. Then, cushioning sutures were performed while the forceps was carefully dislocated. Subsequently, the herniation was resolved using the internal obturator muscle technique as described above in the second case (Figure 3). Postoperative care included elizabethan collar, lavage of the wound once daily with saline solution and bandage. Administration of cephalexin (Keforal[®])¹⁰ every 12 h during 10 days, tramadol (Tramal[®])¹¹ every 6 h for 3 days, dipyron (Novalgina[®])¹⁰ every 6 h for 7 days, ranitidine (Antak[®])⁹

every 12 h during 10 days, and meloxicam (Maxicam[®])¹² every 24 h for 4 days. Doxycycline (Doxifin[®])¹³ was continued for 15 days and second dose of dipropionate imidocarb (Imizol[®])¹⁸ was applied (5 mg/kg/subcutaneous). Ten days following the surgery, skin sutures were removed. Two years postoperative the patient died from unrelated causes. No signs of recurrence were present during this period.

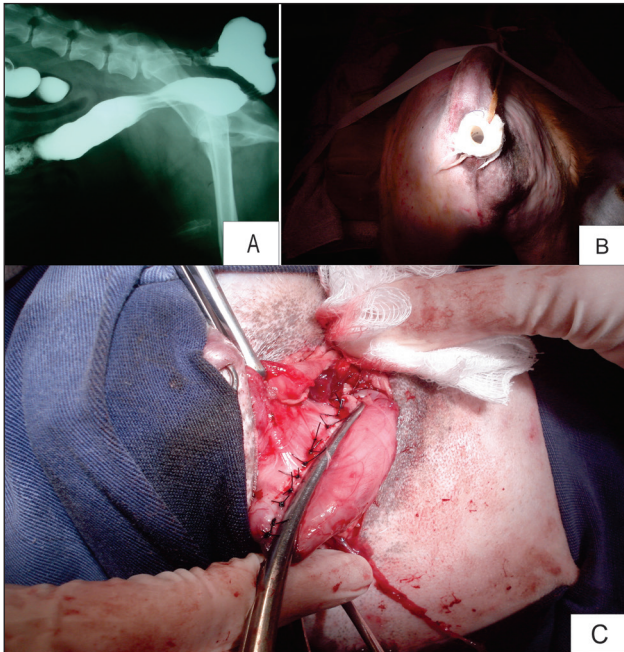


Figure 3. Images of a dog with perineal hernia associated with rectal sacculcation. A- contrast abdominal radiography showing perineal hernia with bowel content and presence of rectal sacculcation. B- After preparation of the surgical field, a lubricated syringe was inserted into the anus to rectal identification during the surgery. C- The rectal sacculcation was retracted and clamped with atraumatic intestinal forceps. Wolff sutures were placed between the forceps and the rectum allowing the sacculcation excision.

Case 4. Polypropylene mesh

A 13-year-old intact male dachshund dog (8.6 kg) was referred to clinical examination due to a 1-year-history complaint of a mass in the right perineal area. The owner also reported rectal prolapse and stranguria noted 2 days prior the consultation. On physical examination, the hernia was non-reducible, painless and presented no signs of inflammation suggesting an incarcerated hernia. Urethral catheterization was not possible. Complete blood count and biochemical tests (alkaline phosphatase, albumin, creatinine, urea, alanine transaminase) were within the parameters. Ultrasound and radiography showed bladder, prostate and bowel contained in hernia sac. The patient underwent to hernia repair with polypropylene mesh and castration.

Tramadol hydrochloride (Tramal[®])¹¹ was administered intramuscular as premedication. The patient was induced with propofol (Diprivan[®])⁴ intravenous. Anesthetic maintenance was achieved with isoflurane (Forane[®])⁵. Epidural was performed using association of lidocaine (Lidovet[®])²¹ and bupivacaine (Neocaína[®])³. The rectal prolapse was repositioned and a purse-string suture was placed. After preparing the surgical site, a dorsoventral skin incision over the hernia was performed. The hernia sac was incised and its content accessed. After cystocentesis, the urinary bladder was manually reintroduced into the abdominal cavity along with the prostate and a portion of the jejunum. Due to the large defect and weakness of the pelvic muscles it was decided to place a polypropylene mesh (Trulene[®])²⁰. The mesh was sutured with a simple interrupted 2-0 nylon (Nylon monofilamentado)²¹. Subcutaneous tissue and skin were closed routinely (Figure 4). After herniorrhaphy, orchiectomy was executed and the purse-string suture was removed. There were no complications during the procedure. A urethral catheter was maintained for 2 days. Postoperative treatment consisted in cephalexin (Keforal[®])¹⁰ every 12 h during 7 days, dipyron (Novalgina[®])¹⁰ every 6 h for 3 days, tramadol (Tramal[®])¹¹ every 12 h for 4 days, and meloxicam (Maxicam[®])¹² every 24 h during 4 days. The patient recovered uneventfully. Ten months after the surgical treatment, the patient presented no complication.

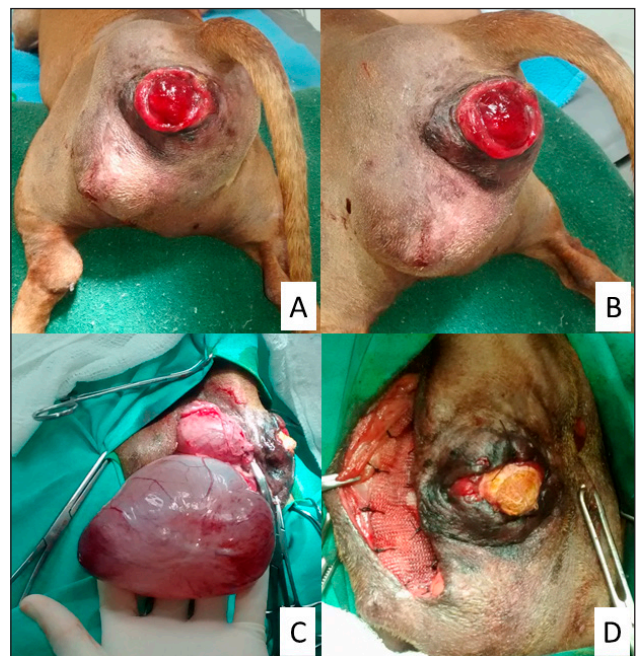


Figure 4. Dog presenting perineal hernia and rectal prolapse. A & B- Patient in sternal recumbency for preparation of the surgical site. Note the mass in the right perineal area and the prolapse. C- The hernia sac was incised and its content accessed. Note the urinary bladder and the prostate. D- A polypropylene mesh was sutured with a simple interrupted 2-0 nylon.

Case 5. Bovine pericardium preserved in 4% formaldehyde

A 7-year-old intact male mixed breed dog (14 kg) was presented to clinical evaluation with swelling lateral to the anus and dyschezia. On examination, the mass in the right perineal area was soft and reducible. Complete blood count and biochemical tests (alkaline phosphatase, albumin, creatinine, urea, alanine transaminase) showed no abnormalities. Abdominal radiography and ultrasound revealed images suggestive of perineal hernia with urinary bladder, prostate and bowel content. The patient was referred to surgery.

Premedication consisted in association of tramadol hydrochloride (Tramal[®])¹¹ and acepromazine (Acepran[®])¹⁴ intramuscular. Anesthetic induction with propofol (Diprivan 1%[®])⁴ and diazepam (Diazepam)³ both intravenous. Anesthetic maintenance with isoflurane (Forane[®])⁵. Epidural was performed using association of lidocaine (Bravet[®])¹⁹ and morfina (Dimorf[®])³. Before the procedure, a urethral catheter and a purse-string suture were placed.

A longitudinal skin incision over the hernia was made and subcutaneous tissue was dissected. After the hernia sac was opened, the bladder, the prostate and the jejunum were reduced manually. An attempt to perform the anatomic herniorrhaphy was made, but due to the extended injury it was decided to place a graft of bovine pericardium (Biopath membrane de pericárdio bovino[®])²², which was preserved in 4% formaldehyde. After lavage with sterile saline solution (Cloreto de Sódio 0,9%)¹³, the pericardium was sutured using a simple interrupted 2-0 polyglactine 910 (Vicryl[®])⁷. Subcutaneous tissue was closed in a continuous appositional pattern with 2-0 polyglactine 910 (Vicryl[®])⁷ and the skin in a simple interrupted pattern using 4-0 nylon (Nylon monofilamentado)²¹. Postoperative medication included amoxicillin (Amoxicil[®])⁹ every 12 h for 7 days, tramadol (Tramal[®])¹¹ every 6 h during 4 days, dipyron (Novalgina[®])¹⁰ every 6 h during 4 days, and meloxicam (Maxicam[®])¹² every 24 h for 4 days. The urethral catheter and the purse-string suture were removed shortly after the procedure and the patient was discharged 24 h after the surgery. Three days later, there was minimal suture dehiscence in ventral portion of the wound associated with mild drainage of serosanguineous fluid. Lavage of the wound was proceeded twice daily with saline solution (Cloreto de Sódio 0.9%)¹³ and elizabethan collar was placed. Skin sutures were removed 12 days after the

procedure and the open wound was completely healed at this moment. Patient follow-up was conducted for 2 years, during this period there was no recurrence or contralateral herniation.

DISCUSSION

Perineal herniations are commonly related to weakness of pelvic diaphragm muscles. However, the etiology involved in this process is undetermined. Studies suggest that relaxin hormone of prostatic origin may be a potential factor in the development of perineal hernia, which might explain its prevalence in older intact male dogs [7]. Our cases were composed by intact male dogs between 8 and 13 year-old, coherent with the general population affected by perineal hernia [5,9]. In addition, it was possible to observe that right-side hernias were prevalent, similar to previously studies where the occurrence of the right side may reach 84% [9].

Clinical signs may vary according to the content of the hernia and the presence of organs strangulation. More common constipation, obstipation, dyschezia and perineal swelling are present. Occasionally, urinary problems, vomiting and diarrhea are reported [1]. Owners in all cases noted swelling in the perianal region, however this sign was neglected in some cases (Case 3, Case 4) and only when signs such as emesis, rectal prolapse, aquesia and stranguria were present the patient was referred to veterinarian's care. This pattern was also observed by other authors [6]. Dogs with anorexia, vomiting, depression and anuria were presented earlier than those with less critical signs.

The content of perineal hernias may present urinary bladder, prostate, small intestine, rectal deviation, sacculum or diverticulum [1]. Bowel and prostate were present in 4 of 5 cases reported in this article. Urinary bladder was present in 2 of them. Urinary bladder retroflexion is known as indicator of poor prognostic and it is commonly associated to obstruction, incontinence and necrosis of the bladder wall [2,6]. However, none of the patients manifested urinary complications. In fact, recent studies revealed that urinary bladder in perineal hernias do not increase postoperative complication or recurrence rates [5,9]. Rectal sacculations generally are associated to chronic hernias [4]. If not treated, it may predispose recurrence due to feces impaction and dyschezia. The case presenting sacculum had 6 months of evolution. During the

rectal palpation, dried feces were present and it was possible to observe an anomaly on rectal anatomy, which was confirmed through radiographic images, as described by literature [3].

Numerous surgical techniques are described, from simple suture repair of pelvic diaphragm to transposition of internal obturator muscle, transposition of semitendinous muscle, use of synthetic mesh, porcine dermal collagen sheet and bovine pericardium. Nowadays, internal obturator muscle transposition is considered the gold standard technique to correct perineal hernias presenting a success rate higher than 90% [1]. However, this success rate is also seen in others techniques, such as semitendinous muscle transposition and polypropylene mesh [10,11]. In this present study, 4 different techniques were performed by four different surgeons. The decision of the technique used was based on surgeon preference and according to the needs of each case. Recurrence did not occur in any of the cases and patients outcome were considered satisfying. We suggest that the technique success is correlated with surgeon's familiarity with the procedure, regardless of the technique used. It is noteworthy, however, that being familiar with the technique also means acknowledge when it is indicated and when it should not be used. For example, in the last case, an anatomic herniorrhaphy was attempted, but after the surgeon evaluation of the perianal muscles it was decided that the technique had great chance of failure and bovine pericardium graft was placed. Grand *et al.* [5] also suggest that the technique used in perineal herniorrhaphy do not have an effect on the postoperative complications.

The time of follow up in these cases reports was considered appropriate since the majority of recurrence occurs between 6 months after initial surgery to 1 year [9]. There were no occurrence of herniation on the contralateral side in any case. It may be explained by the performance of orchiectomy as part of the treat-

ment. The castration of affected dogs reduces both the prevalence and the recurrence rates [7].

Success rate of perineal hernia repair techniques vary in literature. It can be speculated that local factors may influence these results, such as the surgeon ability to perform the technique or to recognize components that adversely affects the surgery. However, it is remarkable that more controlled clinical studies are needed to conclude whether the surgeon factor has an important role in recurrence rate.

MANUFACTURERS

- ¹EMS Farmacêutica. Hortolândia, SP, Brazil.
- ²Laboratório Roche. São Paulo, SP, Brazil.
- ³Cristália Produtos Químicos Farmacêuticos Ltda. Itapira, SP, Brazil.
- ⁴Corden Pharma S.P.A. Caponago, Monza Brianza, Italy.
- ⁵Abbott Laboratories Argentina S.A. Partido de Florencio Varela, Buenos Aires, Argentina.
- ⁶Rioquímica Indústria Farmacêutica. São José do Rio Preto, SP, Brazil.
- ⁷Ethicon Johnson & Johnson do Brasil Indústria e Comércio. São Paulo, SP, Brazil.
- ⁸Cirúrgica Brasil Comercial e Importadora Ltda. São Paulo, SP, Brazil.
- ⁹Glaxosmithkline GSK Brasil. Rio de Janeiro, RJ, Brazil.
- ¹⁰Medley Farmacêutica Ltda. Campinas, SP, Brazil.
- ¹¹Laboratórios Pfizer Ltda. São Paulo, SP, Brazil.
- ¹²Ouro Fino Saúde Animal. Cravinhos, SP, Brazil.
- ¹³Eurofarma. Ribeirão Preto, SP, Brazil.
- ¹⁴Vetnil Indústria e Comércio de Produtos Veterinários Ltda. Louveira, SP, Brazil.
- ¹⁵Sanofi Aventis Brasil. Suzano, SP, Brazil.
- ¹⁶Agener União Saúde Animal. Brasília, DF, Brazil.
- ¹⁷Daiichi-Sankyo Brasil Farmacêutica Ltda. São Paulo, SP, Brazil.
- ¹⁸MSD Saúde Animal. São Paulo, SP, Brazil
- ¹⁹Laboratório Bravet. Rio de Janeiro, RJ, Brazil
- ²⁰Sutures India Private Limited. Karnataka, India.
- ²¹Shalon Suturas. Goiânia, GO, Brazil
- ²²Biomedical Equipamentos e Produtos Médico-Cirúrgicos Ltda. São Paulo, SP, Brazil.

Declaration of interest. The authors report no conflicts of interest. The authors alone are responsible for the content and writing of the paper.

REFERENCES

- 1 Bellenger C.R. & Canfield R.B. 2003.** Perineal hernia. In: Slatter D.H. (Ed). *Textbook of small animal surgery*. 3rd edn. Philadelphia: Saunders, pp.487-497.
- 2 Brissot H.N., Dupré, G.P. & Bouvy B.M. 2004.** Use of laparotomy in a staged approach for resolution of bilateral or complicated perineal hernia in 41 dogs. *Veterinary Surgery*. 33(4): 412-421.
- 3 Dean P.W. & Bojrab M.J. 1996.** Hérnia Perineal. In: Bojrab M.J. (Ed). *Técnicas Atuais em Cirurgia Veterinária*. 3.ed. São Paulo: Roca, pp.410-442.
- 4 Ferreira F. & Delgado E. 2003.** Hérnias perineais nos pequenos animais. *Revista Portuguesa de Ciências Veterinárias*. 98(545): 3-9.

- 5 Grand J.G., Bureau S. & Monnet E. 2013.** Effects of urinary bladder retroflexion and surgical technique on postoperative complication rates and long-term outcome in dogs with perineal hernia: 41 cases (2002–2009). *Journal of the American Veterinary Medical Association.* 243(10): 1442-1447.
- 6 Hosgood G., Hedlund C.S., Pechman R.D. & Dean P.W. 1995.** Perineal herniorrhaphy: Perioperative data from 100 dogs. *Journal of the American Veterinary Medical Association.* 31(4): 331-342.
- 7 Niebauer G.W., Shibly S., Seltenhammer A.P. & Brandt S. 2005.** Relaxin of prostatic origin might be linked to perineal hernia formation in dogs. *Annals New York academy of sciences 2005. Relaxin and Related Peptides: Fourth International Conference.* v.1041 (New York, U.S.A.): 415-422.
- 8 Seim H.B. 2004.** Perineal hernia repair. In: *World congress in small animal veterinary medicine. Proceedings 29.* (Rhodes, USA). v1. Rhodes: Alta Gráfico Publisher, pp.833-836.
- 9 Shaughnessy M. & Monnet E. 2015.** Internal obturator muscle transposition for treatment of perineal hernia in dogs: 34 cases (1998-2012). *Journal of the American Veterinary Medical Association.* 5(3): 321-326.
- 10 Szabo S., Wilkens B. & Radasch R.M. 2007.** Use of polypropylene mesh in addition to internal obturator transposition: a review of 59 cases (2000–2004). *Journal of the American Animal Hospital Association.* 43(3): 136-142.
- 11 Vnuk D., Lipar M., Maticic D. Smolec O., Pecin M. & Brkic A. 2008.** Comparison of standard perineal herniorrhaphy and transposition of the internal obturator muscle for perineal hernia repair in the dog. *Veterinarski Arhiv.* 78(3): 197-2007.

