

Secondary implant stabilization using a modified microplate fixation technique.

Mohamed Hamdy Helal (✉ mohamed.hamdy@dent.tanta.edu.eg)

Oral Medicine, Tanta University

Moustafa Nabil Aboushelib

Alexandria University

Research Article

Keywords: animal study, secondary implant stabilization, microplate fixation technique, osseointegration

Posted Date: October 23rd, 2023

DOI: <https://doi.org/10.21203/rs.3.rs-3436530/v1>

License:   This work is licensed under a Creative Commons Attribution 4.0 International License.

[Read Full License](#)

Additional Declarations: No competing interests reported.

Abstract

Objectives: to enhance initial stability of dental implants placed in compromised bone defects with poor initial stability using a modified fixation technique.

Methods: Two osteotomy defects (6 mm and 4 mm in diameter) were made in the femur of a dog model. Dental implants (4 mm in diameter and 10 mm in length) were placed in the two defects. Microplates were used to enhance the initial stability of the compromised implant placed in the larger defect size without the need for the additional use of a bone graft. A reverse torque test and histomorphometric analysis were performed after eight weeks to assess bone implant contact (n=48).

Results: Both plate and control implants had almost identical bone-to-implant contact ratios, 82.55 ± 0.61 and 82.86 ± 0.69 , respectively. The two tested implants had no statistically significant difference in bone implant contact ($t=1.155$, $p=.260$) nor reverse torque test ($t=1.408$, $p=.173$).

Conclusions: Secondary implant stabilization improved osteointegration of implants suffering from poor initial stability without the need to resort to bone graft or other complicated techniques.

Background

The primary and secondary stability of endo-osseous implants play a significant role for their optimal osseointegration and long-term clinical success [1]. Primary implant stability is determined by the implant direct mechanical contact with the neighboring bone, whereas secondary implant stability is a controlled by direct adaptation of newly created bone on the surface on the inserted implant [2]. Secondary stability is inextricably linked to successful functional loading of the final restoration [3]. The extent of implant stability is determined by the state and quality of the surrounding tissues [4-6]. Primary stability is influenced by a variety of clinical parameters, including bone amount and quality, implant design, and surgical technique [7].

The initial inflammatory stage at the osteotomy site begins with the production of a blood clot, followed by a series of biological healing processes ending in direct bone deposition on the implant surface [5]. To prevent dental implant movement in the early phases, primary stability is required to prevent fibrous encapsulation which can lead to implant failure [1, 8]. However, advanced ridge resorption, massive cyst enucleation [9, 10], tumor resections [11], and a lack of appropriate bone dimensions for the support of oral implants may complicate the rehabilitation plan and affect the treatment modalities. In such compromised conditions, ridge augmentation is recommended to improve bone quality around the compromised implant [12].

As a result, research has concentrated on the development of innovative procedures for ridge augmentation prior to the insertion of dental implants [13, 14]. These extra complicated procedures increase the expenses of treatment and dramatically extend the healing time, in addition to their known risks and expected post-operative complications [15]. Nevertheless, insertion of a dental implant during

grafting procedure may shorten treatment time but that will be on expense of gaining sufficient primary stability.

The aim of this study was to enhance primary stability of dental implants inserted in large defects with poor initial stability using a modified fixation screw technique. The proposed hypothesis was that this technique would enhance implant stability without the need for a grafting procedure.

Methods

Study design

Study protocol was approved by ethics committee of Tanta University's specifying conditions and constraints for conducting and publishing studies involving animal models (No. R-OMPDR-6-23-1) and followed the ARRIVE guideline [16].

Sample size calculation

The sample size was calculated using G-Power software version 3.1.9.2 [17] to detect difference in torque testing. Based on Cochran et al., [18], results, and adopting a power of 80% ($b=0.20$) to detect a standardized effect size in torque testing (primary outcome) of 0.515, and level of significance 5% (α error accepted =0.05), the minimum required sample size was found to be 12 specimens per group (number of groups=4) (Total sample size= 48 specimens)[19, 20].

Experimental animals and their housing and husbandry

In this study, four osteotomy sites were prepared in the femur of 12 adult male dogs (4 and 6 mm in diameter). One standardized implant size (4mm diameter, 10 mm long) was inserted in each osteotomy site. A fixation bar was used to stabilize the implant suffering from compromised primary stability, Fig. 1-a.

The animal-house veterinarian evaluated 12 mature male 2-year-old beagle dogs weighing between 10 and 12 kg to rule out disease and ensure that they were provided with a balanced diet of milk, broth, and meat during the study period. All animals were kept in individual stainless-steel cages with direct access to water, proper ventilation, as well as a 12-hour light/dark cycles. Each animal received two implants in the same femur.

Surgical procedure:

To prevent postoperative infection, each animal was given a prophylactic antibiotic (ampicillin 25 mg/kg body weight) right before the procedure. An expert surgeon (Y.H) performed all the surgeries in a sterile environment in a veterinary operating room. The dogs were given a subcutaneous injection of atropine (0.05 mg/kg; Kwang Myung Pharmaceutical) and after 10 minutes of premedication, anesthesia was induced by injecting a mixture of 2mg/kg Xylazine (Xyla-Ject; Adwia Pharmaceuticals) and 5.5mg/kg

ketamine hydrochloride (KETAMAX-50; Troikaa Pharma) into the cephalic vein of the forelimb and maintaining it with inhalation anesthesia.

The skin over the medial side of the femoral bone was incised, reflected, and the superficial fasciae, muscle tissue, and deep fasciae were also incised bluntly. The periosteum was next incised to reveal the femur shaft, which was ready to receive the dental implants. One sequential osteotomy was started with a pilot drill followed by 2-, 3.5- and 4-mm drill to a depth of 10mm. A second osteotomy, 2 cm apart, was prepared to a size of 6 mm in diameter. Dental implants (B&B DURA-VIT -EV, Italy) of the required size (4 mm in diameter and 10 mm long) were inserted in the two prepared osteotomy sites. A micro plate fixation bar (1.2 System Micro, Plates BioMaterials, Korea) was secured over the compromised implant using the cover screw of the manufacturer and two short fixation pins, Fig 1-b&-c. Deep muscles and fascia were sutured using absorbable suture (4:0 cat gut suture, Trugut, India) followed by skin using non-absorbable sutures (1:0 black silk, Assut, Egypt), and the surgical site was covered with soft cloths to prevent infection, Digital periapical radiographs were taken immediately after surgery and at each subsequent follow-up, Fig 2.

Reverse torque test (RTT):

After 8 weeks of healing, the implants were uncovered and connected to a surgical handpiece connected to a calibrated step motor using a motor driven hex tool. The motor was activated in anticlockwise direction to reach a maximum torque of 50 N.cm over the course of 30 seconds. The test was stopped once the implant started to rotate and rotating torque was reported.

Histomorphometry:

The animals were sacrificed with an overdose of thiopental sodium after 8 weeks, and their femur blocks were dissected. The blocks were promptly fixed for one week in 4% buffered formaldehyde. The specimens were next dehydrated in rising ethanol concentrations (50, 70, 90, and 100%) using a dehydration machine (ASP 300S, Leica Biosystems) with agitation and vacuum. The blocks were embedded in clear chemically polymerized methyl methacrylate resin and cut in a coronal-apical plane using a precision-cutting machine (Metkon's Micracut150 precision cutter), then ground and polished with 800-grit silicon carbide paper. After staining, (Stevenes blue and Van Gieson picrofuchsin), the sections were examined using a light stereomicroscope (BX61; Olympus Corp) equipped with a high-resolution digital camera (E330; Olympus Corp). Bone implant contact (BIC) was calculated as the amount of new bone in direct contact with implant surface and was calculated as a percentage of implant perimeter calculated from the most central section.

Data were collected and entered to the computer using SPSS (Statistical Package for Social Science) program for statistical analysis (ver 25)[21]. Data were entered as numerical or categorical, as appropriate. Kolmogorov-Smirnov test of normality of the distribution of the variables was not statistically significant, so parametric statistics was adopted [22]. Data were described using minimum, maximum, mean, standard deviation, standard error of the mean, 95% Confidence Interval of the mean,

25th to 75th percentiles. Comparisons were carried out between two independent normally distributed variables using the independent (Student's) t-test. An alpha level was set to 5% with a significance level of 95%.

Results

All wounds healed uneventfully without any complications. X-ray images revealed successful osteointegration and complete healing of the larger osteotomy site after 8 weeks of healing time as evident by presence of high-density bone around the inserted implants, Fig.3. All inserted implants succeeded 50 N.cm *RTT* except one implant belonging to the control group which recorded 43 N.cm on reverse rotation.

Statistical analysis revealed that there was no statistically significant difference in BIC ($t=1.155$, $p=.260$) nor *RTT* ($t=1.408$, $p=.173$) as both implants had almost identical bone to implant contact ratio, 82.55 ± 0.61 and 82.86 ± 0.69 respectively, Table 1 & Fig.4. Histological examination of the prepared hard tissue sections revealed deposition of high-density bone around both implants and adequate tissue remodeling as evident by the formation of homogenous bone cell lacunae and vascularization of surrounding bone, Fig.3.

Discussion

In many clinical situations, a dental implantologist is faced with a situation where bone quality and dimensions compromise the initial stability of the inserted dental implant. In such cases, the surgeon tries to gain some stability by engaging 2 or 3 mm from apical or crestal bone and filling the remainder of the defect size with a bone graft material [23]. Even in such cases, poor initial stability may result in future implant displacement [8, 23]. A further drawback is the extended healing time which could exceed several months. Micro-movement of compromised implants could lead to fibrous tissue encapsulation, dislodgment into vital areas as maxillary sinuses or sublingual region, and loss of surrounding bone graft material [24]. In this study, microplate fixation plate was used to secure a totally loose dental implant which did not engage any bony wall of the prepared osteotomy. In this extreme condition, the implant was entirely dependent on the secondary initial stability offered by the fixation microplate. The gap between the implant surface and the prepared osteotomy (2 mm in diameter) was left to heal without augmentation with bone graft. This contrasts with previous study reported by [25], in which a mineral-organic adhesive have been used to stabilize an implant put in a region lacking primary stability with engagement of 2mm apical to the prepared osteotomy. The results with the adhesive materials were substantially better than those with a bovine bone graft material, which did not stabilize the implant and showed significantly less creation of bone-to-implant contact throughout a 4-month healing period.

Reverse torque test indicated that the compromised implant was able to achieve maximum stability after 8 weeks of healing which was also confirmed analyzing the provided x-rays where the entire defect size was repaired using remodeling of the initially formed blood clot, Fig.2. Secondary implant fixation

resulted in successful osseointegration which reveals the marvelous capacity for bone regeneration without the need for additional tissue guidance or protection. Indeed, the defect size between the compromised implant and the surrounding bone was relatively small to be easily filled with bone, the idea that the compromised implant did not have any contact with the surrounding bone reveals that secondary implant stabilization was successful in providing sufficient stability during early healing phase. The proposed hypothesis was thus accepted, similar to previous findings for the implants which lacked initial stability [26].

The current study's findings on osseointegration contrasted with those of a prior study reported by Sivoilella et al., [27], which found osteogenesis on the surface of the loosely implanted implants, one implant served as the control, while the other two were inserted into recipient sites, leaving a 0.7 mm (small) and 1.2 mm (large) circumferential and periapical prepared defect, respectively. To keep the implants stable and free from contact with the implant bed, passive fixation plates were used to stabilize all the implants. While larger faults required several jumps from the woven bone to span the gap, imperfections less than one millimeter gave the opportunity for the newly produced bone to traverse the gap by a single jump [28]. However, a very low degree of osseointegration was seen even in the tiny flaws. This contradicts our findings because in our trial, the gap was 2 mm and osseointegration had already taken place. This might be because we used implants with threads which allowed newly created bone deposition unlike using customized implants without threads that used in the previous study.

Examination of the prepared histological sections revealed direct bone implant contact covering the majority of implant surface both the two inserted implants. Dense and vascularized bone formation in direct contact with implant surface indicated proper healing of the larger osteotomy site prepared around the compromised implant, Fig.3. Secondary implant stabilization could be performed using guided micro-plate design for complicated cases or those with multiple compromised implants. This is in the agreement with previous study [26] that revealed the ability of a mineral-organic adhesive to stabilize an implant put in a region lacking primary stability, allow native bone to replace the implant over time without losing structural support, and preserve the crestal bone to the top of the implant.

In cases of one or two wall defect, a bone graft protected by a guidance membrane is the classical approach for insertion of a dental implant in such a compromised osteotomy defect. Secondary implant stabilization may improve the clinical outcome of such compromised implant.

Conclusions

Within the limitations of this study, secondary implant stabilization is a promising method for implants placed in compromised osteotomy defect.

Abbreviations

BIC: Bone implant contact; RTT: Reverse torque test; n : Number of patients; Min-Max: Minimum – Maximum; S.D.: standard deviation; SEM: standard error of the mean; CI: Confidence interval; df: degree of freedom; t: independent sample t-test.

Declarations

Acknowledgement

The authors want to thank Dr. Yasmin Hamdy for performing the surgical procedures.

Author contributions:

Mohamed Hamdy Helal: contributed materials and wrote the paper.

Moustafa Nabil Aboushelib: analyzed and interpreted the data, contributed to reagents, materials, analysis tools or data, and wrote the paper.

Funding

No funding

Availability of data and materials

The data that support the findings of this study are available from the corresponding author upon reasonable request.

Ethics approval and consent to participate.

The animal experiment has been approved by the ethics committee of Tanta University (No. R-OMPDR-6-23-1)

Consent for publication

Not applicable.

Competing interests/Conflict of interest

The authors declare that they have no conflict of interests.

Availability of data and materials

The datasets used and/or analyzed during the current study are available from the corresponding author on reasonable request.

Author details

1. Oral Medicine, Periodontology, Oral Diagnosis and Radiology Department, Faculty of Dentistry, Tanta University, Egypt. Email: mohamed.hamdy@dent.tanta.edu.eg

2. Dental Biomaterials Department, Faculty of Dentistry, Alexandria University, Egypt. Email: moustafaaboushelib@gamil.com

References

1. Javed, F., et al., *Role of primary stability for successful osseointegration of dental implants: Factors of influence and evaluation*. Interv Med Appl Sci, 2013. **5**(4): p. 162-7.
2. Greenstein, G., et al., *Clinical recommendations for avoiding and managing surgical complications associated with implant dentistry: a review*. J Periodontol, 2008. **79**(8): p. 1317-29.
3. Davies, J.E., *Mechanisms of endosseous integration*. Int J Prosthodont, 1998. **11**(5): p. 391-401.
4. Javed, F. and G.E. Romanos, *Impact of diabetes mellitus and glycemic control on the osseointegration of dental implants: a systematic literature review*. J Periodontol, 2009. **80**(11): p. 1719-30.
5. Cochran, D.L., et al., *Bone response to unloaded and loaded titanium implants with a sandblasted and acid-etched surface: a histometric study in the canine mandible*. J Biomed Mater Res, 1998. **40**(1): p. 1-11.
6. Javed, F. and K. Almas, *Osseointegration of dental implants in patients undergoing bisphosphonate treatment: a literature review*. J Periodontol, 2010. **81**(4): p. 479-84.
7. Romanos, G.E., *Bone quality and the immediate loading of implants-critical aspects based on literature, research, and clinical experience*. Implant Dent, 2009. **18**(3): p. 203-9.
8. Lioubavina-Hack, N., N.P. Lang, and T. Karring, *Significance of primary stability for osseointegration of dental implants*. Clin Oral Implants Res, 2006. **17**(3): p. 244-50.
9. AboulHosn, M., et al., *Decompression and Enucleation of a Mandibular Radicular Cyst, Followed by Bone Regeneration and Implant-Supported Dental Restoration*. Case Rep Dent, 2019. **2019**: p. 9584235.
10. Ettl, T., et al., *Jaw cysts - filling or no filling after enucleation? A review*. J Craniomaxillofac Surg, 2012. **40**(6): p. 485-93.
11. Troiano, A., et al., *Salvage of Dental Implant Located in Mandibular Odontogenic Cyst. A Conservative Surgical Treatment Proposal*. Dent J (Basel), 2020. **8**(2).
12. Kim, Y.K. and J.K. Ku, *Ridge augmentation in implant dentistry*. J Korean Assoc Oral Maxillofac Surg, 2020. **46**(3): p. 211-217.
13. Aboushelib, M.N. and R. Shawky, *Osteogenesis ability of CAD/CAM porous zirconia scaffolds enriched with nano-hydroxyapatite particles*. Int J Implant Dent, 2017. **3**(1): p. 21.
14. Helal, M.H., et al., *Osteogenesis ability of CAD-CAM biodegradable polylactic acid scaffolds for reconstruction of jaw defects*. J Prosthet Dent, 2019. **121**(1): p. 118-123.

15. Jensen, A.T., S.S. Jensen, and N. Worsaae, *Complications related to bone augmentation procedures of localized defects in the alveolar ridge. A retrospective clinical study.* Oral Maxillofac Surg, 2016. **20**(2): p. 115-22.
16. Kilkeny, C., et al., *Animal research: reporting in vivo experiments: the ARRIVE guidelines.* Br J Pharmacol, 2010. **160**(7): p. 1577-9.
17. Faul, F., et al., *G*Power 3: a flexible statistical power analysis program for the social, behavioral, and biomedical sciences.* Behav Res Methods, 2007. **39**(2): p. 175-91.
18. Cochran, D.L., et al., *Immediate Dental Implant Stabilization in a Canine Model Using a Novel Mineral-Organic Adhesive: 4-Month Results.* International Journal of Oral & Maxillofacial Implants, 2020. **35**(1).
19. Charan, J. and T. Biswas, *How to calculate sample size for different study designs in medical research?* Indian J Psychol Med, 2013. **35**(2): p. 121-6.
20. Walters, S.J., et al., *Sample size estimation for randomised controlled trials with repeated assessment of patient-reported outcomes: what correlation between baseline and follow-up outcomes should we assume?* Trials, 2019. **20**(1): p. 1-16.
21. IBM Corp., *IBM SPSS Statistics for Windows, Version 25.0.* Released 2017, IBM Corp.: Armonk, NY.
22. Field, A., *Discovering Statistics Using IBM SPSS Statistics.* 4th ed. 2013, London, California, New Delhi: SAGE Publications Ltd.
23. Kochar, S.P., A. Reche, and P. Paul, *The Etiology and Management of Dental Implant Failure: A Review.* Cureus, 2022. **14**(10): p. e30455.
24. Noskovicova, N., B. Hinz, and P. Pakshir, *Implant Fibrosis and the Underappreciated Role of Myofibroblasts in the Foreign Body Reaction.* Cells, 2021. **10**(7).
25. Cochran, D.L., et al., *Immediate Dental Implant Stabilization in a Canine Model Using a Novel Mineral-Organic Adhesive: 4-Month Results.* Int J Oral Maxillofac Implants, 2020. **35**(1): p. 39-51.
26. Song, Y.W., et al., *Secondary stability achieved in dental implants with a calcium-coated sandblasted, large-grit, acid-etched (SLA) surface and a chemically modified SLA surface placed without mechanical engagement: A preclinical study.* Clin Oral Implants Res, 2021. **32**(12): p. 1474-1483.
27. Sivolella, S., et al., *Osteogenesis at implants without primary bone contact - an experimental study in dogs.* Clin Oral Implants Res, 2012. **23**(5): p. 542-9.
28. Botticelli, D., et al., *Appositional bone formation in marginal defects at implants.* Clin Oral Implants Res, 2003. **14**(1): p. 1-9.

Tables

Table 1 Bone to Implant Contact (BIC) and Reverse Torque Test (RTT) measurements (mean ± standard deviations)

	Groups		Test of significance <i>p</i>
	Plate implant (n=12)	Cotnrol implant (n=12)	
Bone to Implant Contact (BIC) (%)			
- Min. – Max.	81.40 – 83.40	81.40 – 83.80	$t_{(df=22)}=1.155$
- Mean±SD.	82.55 ± 0.61	82.86 ± 0.69	
- SEM	0.18	0.20	$p=.260$ NS
- 95% CI of the mean	82.16 – 82.94	82.42 – 83.30	
- 25 th percentile-75 th percentile	82.10 – 82.95	82.70 - 83.30	
Reverse Torque Test (RTT) (N.cm)			
- Min. – Max.	48.00 – 55.00	48.00 – 57.00	$t_{(df=22)}=1.408$
- Mean±SD.	50.92 ± 2.07	52.42 ± 3.06	
- SEM	0.60	0.88	$p=.173$ NS
- 95% CI of the mean	49.60 – 52.23	50.47 – 54.36	
- 25 th percentile-75 th percentile	49.50 – 52.00	50.00 – 55.00	

*: Statistically significant ($p<.05$)

Figures

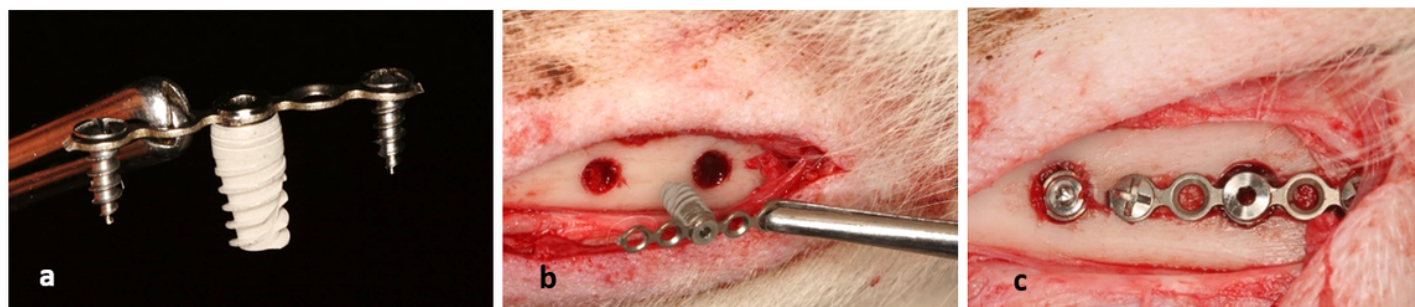


Figure 1

Digital photograph showing the mechanism of secondary microplate fixation technique (a). Digital photograph showing osteotomy sites before securing microplate. 6mm defect size on the right (b). Digital photograph showing osteotomy sites after securing microplate using mini screws. Compromised implant on the right not touching any bone wall (2mm gap size) (c).

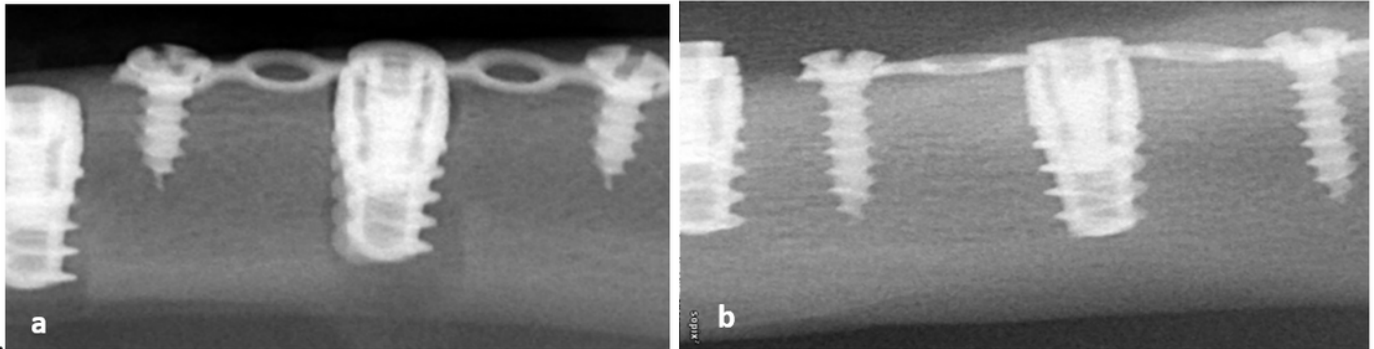


Figure 2

Digital x-ray image showing dental implants on day of insertion. Notice larger osteotomy site appearing around compromised implant on the right (a). Digital x-ray image showing the compromised dental implant after 8 weeks. Notice complete healing of the large osteotomy site (b).

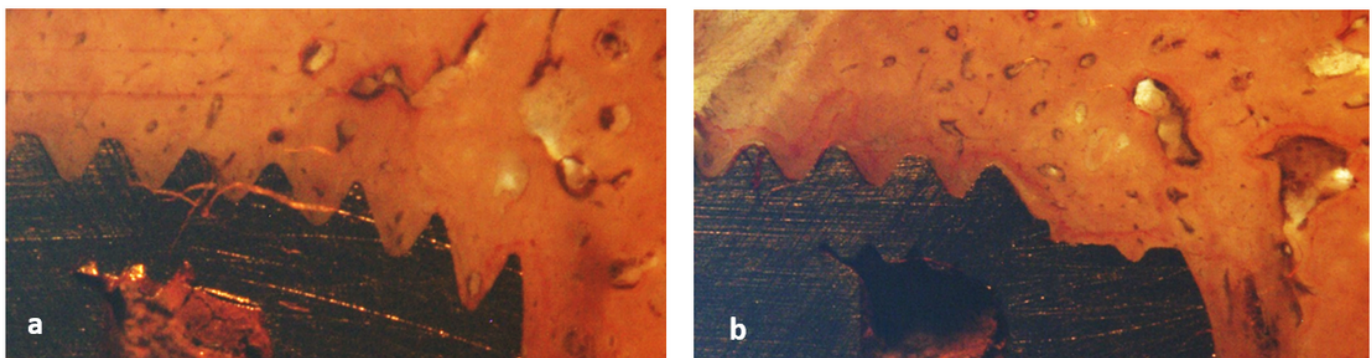


Figure 3

Histological section showing complete osteointegration around compromised implant after 8 weeks healing time (a). The histological section shows complete osteointegration around control implant after 8 weeks healing time (b).

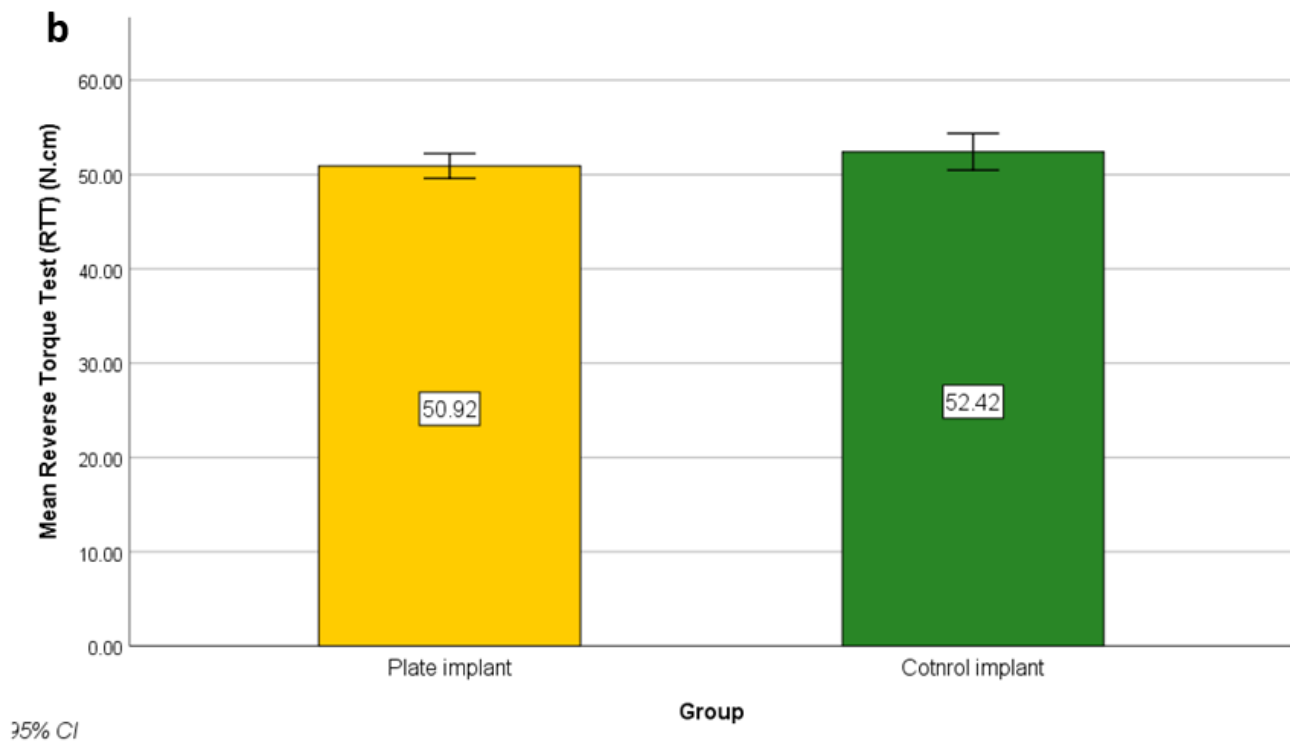
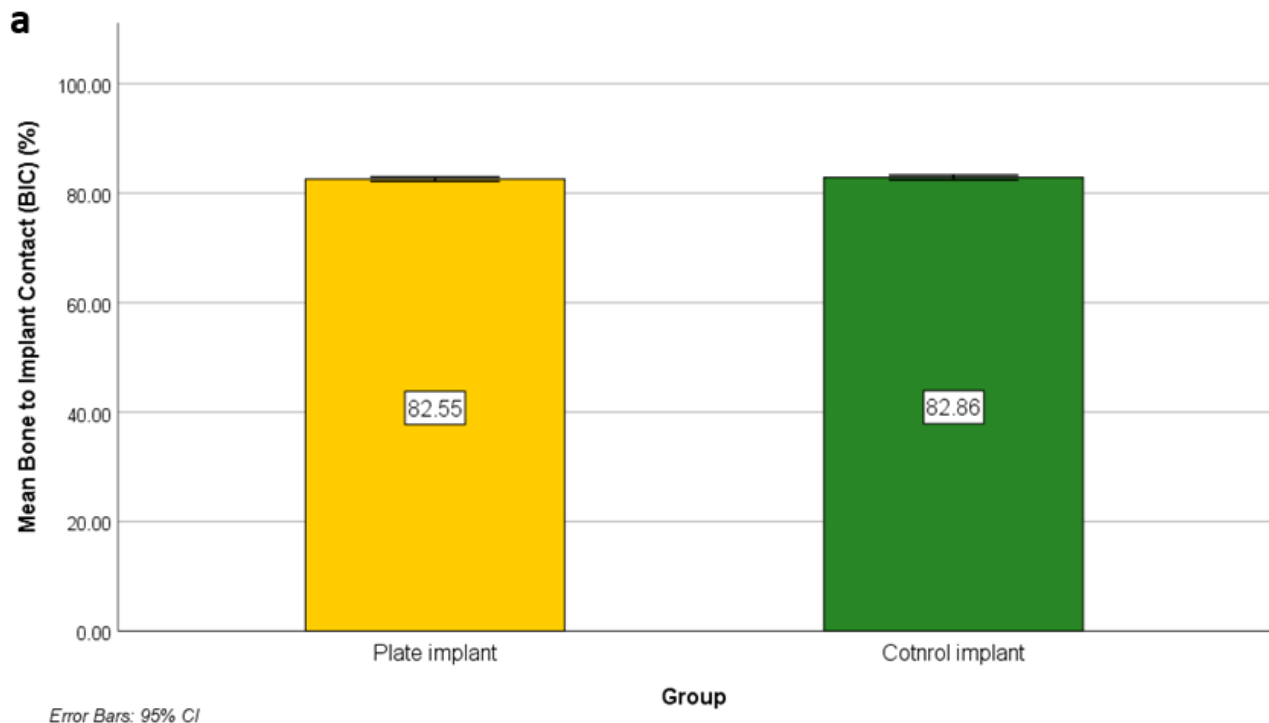


Figure 4

Simple Bar of Mean Mean Reverse Torque Test (RTT) (N.cm) (\pm 95% CI) by Group(a). Simple Bar of Mean Bone to implant Contact (BIC) (%) (\pm 95% CI) by Group (b).