

# Functional Outcome Following Concurrent Medial Meniscus Posterior Horn Root Repair during High Tibial Osteotomy in Early Medial Compartment Osteoarthritis

Anoop Pilar<sup>1</sup>, Madan Mohan M<sup>1</sup>, Sunil L K<sup>1</sup>, Surendra Babu S<sup>1</sup>, Padmanabhan Sekaran<sup>2</sup>, Rajkumar S. Amaravathi<sup>1</sup>

## Abstract

**Background:** Meniscal root tears cause biomechanical changes comparable to a total meniscectomy. The resultant compromise in hoop stress, leads to decreased tibiofemoral contact area and increased contact pressure. This will lead to early arthritis. The meniscus root tear causes more detrimental changes in people with varus alignment of the lower limb. This increases the chances of progression to arthritis, causing joint pain and functional limitation, eventually necessitating early replacement surgery. Surgical management with repair of the meniscus, with corrective osteotomy restoring the normal anatomy, has been reported to improve clinical and functional outcomes and delay the replacement surgery. This study aimed to evaluate the functional outcome following concurrent Medial meniscus posterior horn root (MMPHRTs) repair during open medial wedge high tibial osteotomy (HTO) with medial osteoarthritis.

**Methods:** We performed posterior horn root repair with open medial wedge HTO in 9 patients, between 2016 and 2021. The mean follow-up of patients was 2 years. The mean Lysholm and IKDC scores showed significant improvement (7 had excellent and 2 had satisfactory scores). Patients returned to their expected activity of daily living.

**Conclusion:** Concurrent MMPHRT repair along with medial open wedge HTO for medial compartmental osteoarthritis with varus alignment gives good results and has shown good clinical and radiological outcome on short term follow-up.

**Keywords:** Meniscal root tear, Medial open wedge HTO, Preoperative planning, Outcome.

## Introduction

The meniscus is a crescent-shaped fibro cartilaginous tissue that is necessary for joint stability, congruity, and proprioception [1, 2]. The medial and lateral meniscus maintain 90 and 70% of the hoop tension, respectively [3]. The meniscus circumferential collagen fibres translate axial forces into tensile forces. As a result, any radial tear in the meniscus will result in the loss of circumferential tension. Loss of circumferential hoop tension raises joint contact pressure, leading to osteoarthritis development [4-7].

Medial Meniscus Posterior Horn Root Tears (MMPHRTs)

cause a reduction of meniscal hoop tension, which can progress to medial compartment osteoarthritis [4-7]. Arthroscopic MMPHRT repair is a well-established procedure and known to decelerate articular cartilage degeneration. The varus deformity of the lower extremities, which is frequent in medial knee osteoarthritis(OA), is a significant predictor of meniscal healing and long-term results after MMPHRT repair [8-13]. Hence, MMPHRT, in combination with deformity reduction, is also required to decompress unicompartamental overload.

For medial compartment OA with varus malalignment, medial open-wedge high tibial osteotomy (OWHTO) is a joint preservation procedure [14-17]. HTO transfers the weight-bearing axis which is deviated. The medial open wedge osteotomy improves the medial proximal tibial angle while lowering the medial compartmental pressure. MMPHRT is a typical finding in osteoarthritic knees during OWHTO. The prevalence of root tear of medial meniscus has been widely recorded, accounting for 80 percent of osteoarthritis patients [18-19].

<sup>1</sup>Department of Orthopaedics, St Johns Medical College and Hospital, Bangalore, Karnataka, India.

<sup>2</sup>Department of Physiotherapy and Rehabilitation, Sparsh Hospital, Bangalore, Karnataka, India.

### Address of Correspondence :

Dr. Rajkumar S. Amaravathi,  
Department of Orthopaedics, St Johns Medical College and Hospital, Bangalore,  
Karnataka, India.

E-mail: rajkumar\_as@yahoo.co.in

Submitted: 08/01/2022; Reviewed: 15/01/2022; Accepted: 20/01/2022; Published: 10/02/ 2022

Journal of Karnataka Orthopaedic Association | Available on [www.jkoaonline.com](http://www.jkoaonline.com) | DOI:10.13107/jkoa.2022.v10i01.045

This is an Open Access article distributed under the terms of the Creative Commons Attribution Non-Commercial-Share Alike 4.0 License (<http://creativecommons.org/licenses/by-nc-sa/4.0>) which allows others to remix, tweak, and build upon the work non-commercially as long as appropriate credit is given and the new creation are licensed under the identical terms.

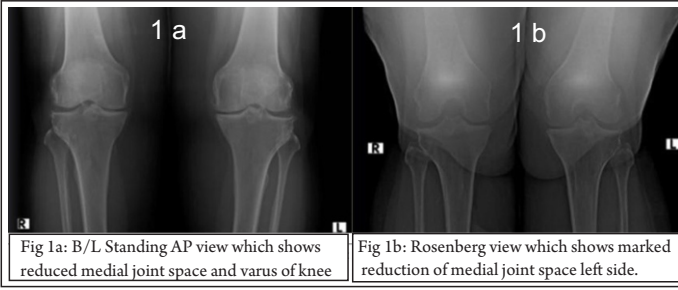


Fig 1a: B/L Standing AP view which shows reduced medial joint space and varus of knee

Fig 1b: Rosenberg view which shows marked reduction of medial joint space left side.

Joint preservation procedures aim to prolong the time to total knee arthroplasty, with reported 10-year survival rate of around 56% to 79% [20-23]. By restoring medial meniscal hoop tension and the tibiofemoral contact surface during HTO, concurrent MMPHRT repair may be a viable method to avoid OA progression. Studies have shown that after HTO, denuded articular cartilage will be covered, and OA progression will be prevented [20-23]. However, the quality of the resultant fibrous cartilage is not as good as the original hyaline cartilage [24].

Our study hypothesized that medial open wedge HTO with concurrent medial meniscus root repair, is an ideal joint preserving procedure for patients with varus malalignment along with medial meniscus root tear. The above procedure would give long term benefit to patient and slowdown the progression of osteo arthritis in the involved extremity.

**Methods and Material**

Approval from ethics committee of the institution was obtained for this longitudinal observational study. Between 2016 and 2021, 9 patients who underwent concurrent posterior horn root repair with open medial wedge high tibial osteotomy were included in the study. Patients with grade 4 Kellgren & Lawrence osteoarthritic changes, and those who did not meet the standard criteria for HTO were excluded.

Patients reported hearing a pop noise while climbing the stairs or getting up from the low chair. The main symptom was pain, difficulty to sit cross legged and/or disturbed sleep at night due to pain. Clinical evaluation showed postero-medial joint line tenderness, positive standard tests for the meniscus and varus deformity of the involved limb.

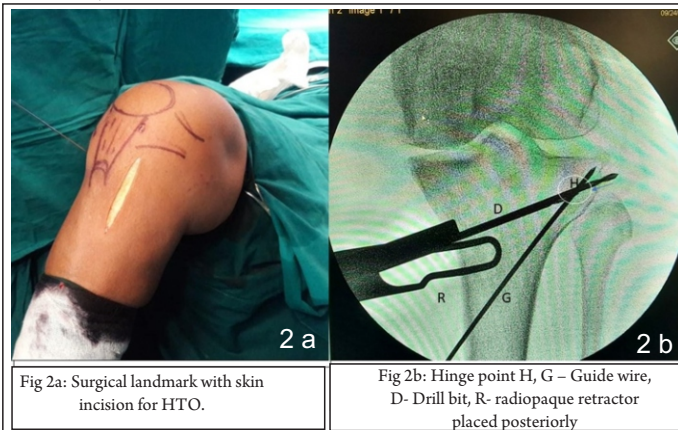


Fig 2a: Surgical landmark with skin incision for HTO.

Fig 2b: Hinge point H, G - Guide wire, D - Drill bit, R - radiopaque retractor placed posteriorly

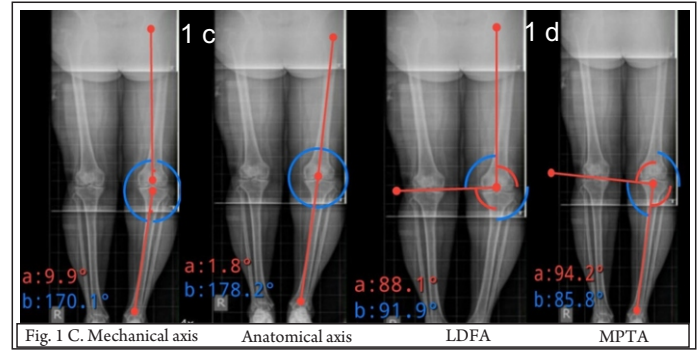


Fig. 1 C. Mechanical axis Anatomical axis LDFA MPTA

Imaging included standard weight bearing radiographs (Fig. 1a-1d): anteroposterior (AP), lateral (LAT), standing AP with 45° of knee flexion (Rosenberg view), merchant views. Long leg alignment films with patella central was taken for the assessment of the mechanical axis and to look for the malalignment. Standard 3-Tesla MRI of the involved knee showed the root tear, with highest accuracy in coronal T2 weighted image. “Ghost sign” in T1 sagittal image which typically shows increased signal or absence of dark signal found near the posterior root. Cartilage mapping also was done to look for the status of the cartilage.

The patients were initially treated conservatively with analgesics, lifestyle modification and physiotherapy to relieve pain. Failure to respond to conservative management was considered for intervention. Preoperative planning was done for the corrective osteotomy by the Picture Archiving and Communication System (PACS) method and with printed radiographs of the long leg X-ray. Mechanical joint angles especially the lateral proximal femur angle (LPFA), lateral distal femur angle (LDFA), medial proximal tibial angle (MPTA), lateral distal tibial angle (LDTA) and proximal posterior tibial angle (PPTA) were measured and analyzed to choose the bone for deformity correction. Miniaci method [15, 16, 20-24] was used in order to select the correction angle and gap required in OWHTO. Those with varus angle more than 4 degrees were considered for OWHTO.

Surgery was done under tourniquet control and image intensifier guidance. Our preferred surgical technique for the repair of MMPHRT is arthroscopic transosseous transtibial single tunnel pullout repair technique as described by Laprade

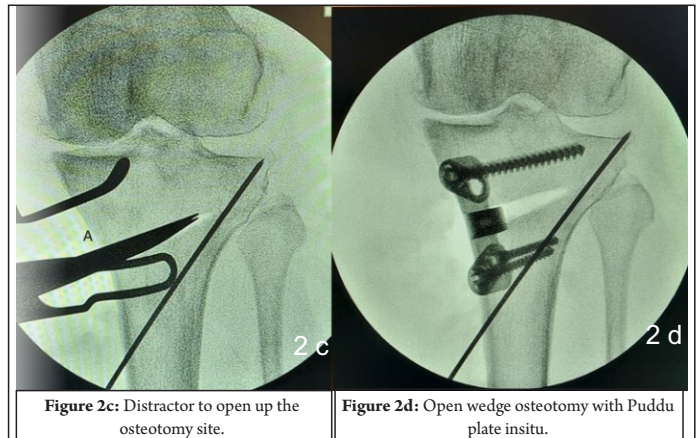


Figure 2c: Distractor to open up the osteotomy site.

Figure 2d: Open wedge osteotomy with Puddu plate insitu.

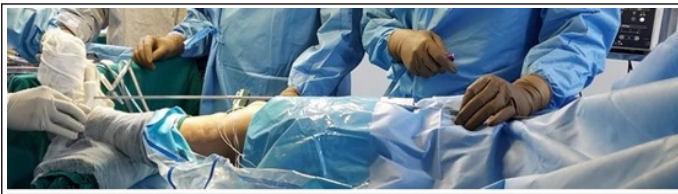

Fig 3a: Intraop marking of mechanical axis using guide wire.

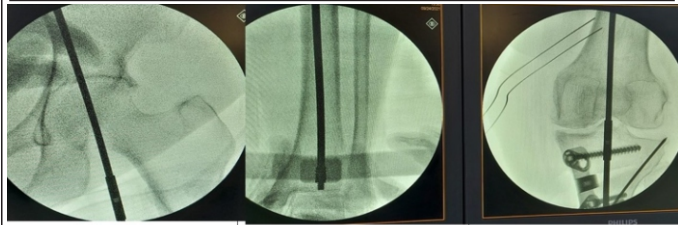


Fig 3b: Guide wire passing through centre of head.

Fig 3c: Guide wire passing through centre of ankle

Fig 3d: Guide wire passing through centre of tibial spine

et al. Standard antero-medial and anterolateral parapatellar portals were created, and the torn stump of meniscus was debrided down to a bleeding bone trough by an arthroscopic shaver. Meniscus was probed to identify the tear and to determine reparability of root. It was followed by a biplanar medial open wedge HTO through a vertical incision of about 6-8 cm on the anteromedial border of the tibia medial to the tibial tuberosity (Fig. 2a). Sartorius fascia was dissected and upper border of PES anserinus was identified, a reverse L shaped incision was placed with the horizontal limb of the incision 1cm below the joint line and vertical limb of the incision close to the tibial tuberosity. Sub-periosteal mobilisation of the superficial MCL was done.

A 2.5 mm drill bit (2.5-3.2) was passed from medial to lateral direction towards the hinge point. Hinge point is at the level of Gerdy's tubercle 10mm medial to the lateral cortex. Care was taken to prevent hinge fracture (Fig. 2b). The K-wires were placed under fluoroscopic guidance for the cut, which was directed towards the hinge point. Once the placement was satisfactory, the posterior dissection was carried out and radio-opaque retractors were placed to protect the neuro-vascular structure. Osteotomy cut was taken with the help of an oscillating saw, which was advanced upto 2/3<sup>rd</sup> the width of the

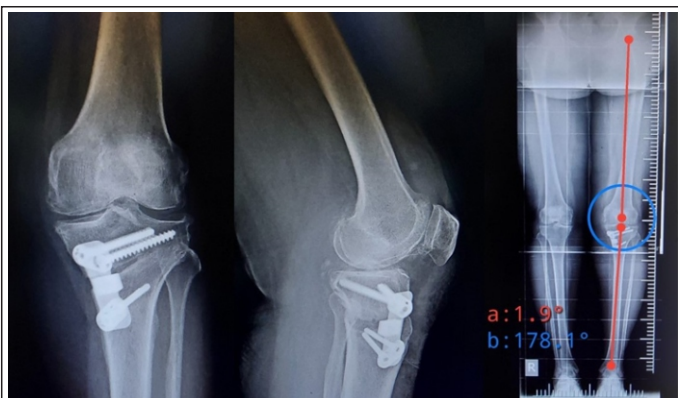

Fig 5a: Postoperative radiograph which shows osteotomy site healing with implant insitu

Fig 5b: lateral view of post-operative radiograph with plate insitu.

Fig 5c: postoperative scanogram

a: 1.9°  
b: 178.1°

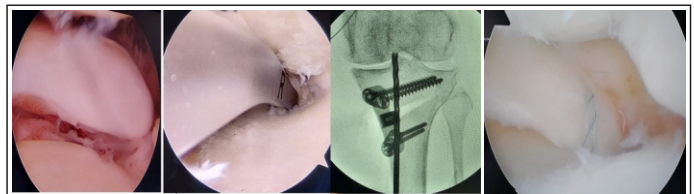


Fig 4a: Diagnostic arthroscopy which shows MMPHRT

Fig 4b: Tibial jig which is placed for root repair

Fig 4c: Intra op C arm pic showing drill bit in tunnel for meniscal root repair.

Fig 4d: MMPHRT which is anchored back to its attachment

tibial plateau. Separate ascending cut of the biplanar osteotomy was done at an angle of 110 degrees, 1-2 cm behind the tibial tuberosity parallel to anterior tibial margin in the frontal plane. The osteotomy was opened gradually using the chisel to achieve desired gap by using specially calibrated spreading device (Fig. 2c). Intraoperatively alignment rod was placed from the center of the hip joint to the center of the ankle joint passing along the center of the knee joint to check alignment (Fig. 3a-3d). Once the alignment was confirmed a Puddu plate (fig 2d) (Arthrex, Naples, FL, USA) was positioned in the osteotomy site. Arthroscopically two bites were taken at 5-7 mm medial to the torn edge of the meniscus and the second 1 cm from the 1st stitch using the shuttle relay method with No. 2 nonabsorbable suture (Healthium Pvt Ltd, Peenya, BLR) which was passed through the meniscus root by using Knee Scorpion (Arthrex, Naples, FL) (Fig. 4a, 4b). Various stitch configurations have been described, but we prefer a modified Mason–Allen suture technique pattern. Sutures were thereafter retrieved from the lateral portal. An anatomical side specific root repair guide (Smith & Nephew Endoscopy, Andover, MA), was introduced from the medial portal, and it was centered on the footprint of root. A guide pin was advanced from the proximal medial tibia to the guide tip. A 5 mm tunnel is drilled over the protected guide pin, carefully breaching the tibial surface (Fig. 4c). Sutures were then retrieved through the tunnel with the help of inverted beath pin and shuttled exteriorly where they were secured with the suture disc and sometimes sutures were tied to plate (Fig. 4d). Wound was closed in layers and post operatively patient was put on a hinged knee locking brace. Rehabilitation was started the next post-operative day with quadriceps strengthening, ankle pump and protected straight leg raise, non-weight bearing walking and restricted range of movement from 0-60 degrees for 4 weeks. At 5 weeks postoperatively X-rays were done, healing at the osteotomy site was assessed and then

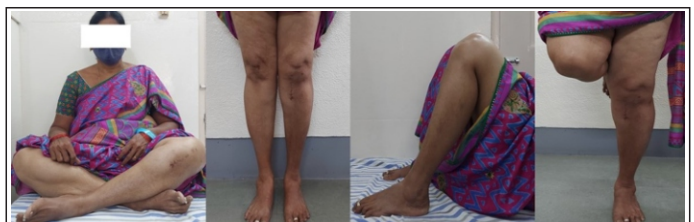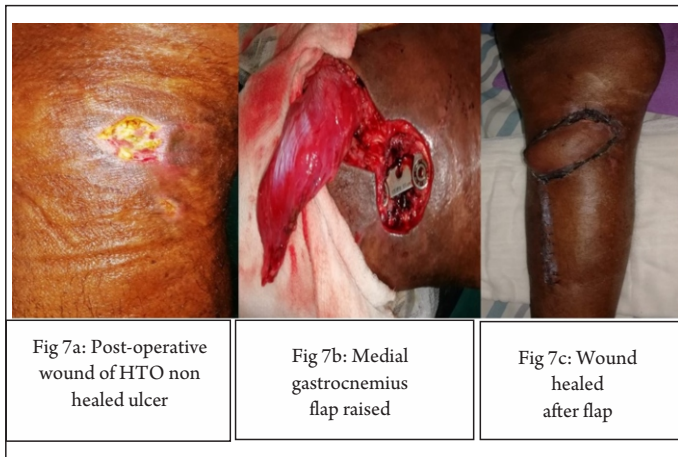


Fig 6a: 6 months post procedure in cross leg position

Fig 6b: limb which is in normal alignment

Fig 6c: knee flexion which is comparable to normal limb

Fig 6d: single leg stance post procedure



assisted toe touch weight bearing was allowed, and range of motion (ROM) of the knee was increased gradually. Full weight-bearing was permitted after 8 weeks postoperatively. Sports activity, cross-legged sitting and walking on uneven surface were permitted 6 months postoperatively. The Lysholm and IKDC scores along with the KL grading was assessed on posteroanterior radiograph of the knee joint in a standing position with 45° of flexion along with long leg scanograms were done both preoperatively and at the end of 6 months and 1 year. Any changes in the grade was considered progression of osteoarthritis.

## Results

There were 7 female and 2 male patients with an average BMI of 24.56 kg/m<sup>2</sup> (Range 22–27.12 kg/m<sup>2</sup>) with mean age of 45±5.1 years (40-50 yrs). The right leg was predominantly involved (Rt: Lt:: 8:1). The average varus was 8 degrees (Range 7-10). Intraoperatively 8 patients had type 2 meniscus tear and 1 had type 4 according to Laprade's classification. According to Outerbridge 5 patients had tibial side type 1 lesions, 2 patients had type 2 on the medial tibial condyle, 2 patients had type 3 in both medial femoral and tibial condyles. Preoperatively all patients had poor Lysholm and IKDC Scores.

The mean followup of patients was 2 years with shortest being 6 months and longest 4 years. The mean Lysholm and IKDC scores showed significant improvement, with 7 excellent and 2 satisfactory scores. All patients had good clinical and radiological outcome. All attained good knee range of movement and showed satisfactory union at osteotomy site along with normal alignment at end of 3 months (Fig. 5a-5b), (Fig. 6a-6d). Patients returned to their expected activity of daily living. Three out of 9 (33.33%) showed progression by at least one grade on Xray KL grading and six out of Nine (66.66%) showed no progression. None desired to have arthroplasty at latest follow-up.

One patient had superficial skin necrosis. He was managed with medial gastrocnemius flap (Fig. 7a-7c) and went on to heal with no further complications.

## Discussion

Lower medial proximal tibial angle or varus malalignment predispose to joint degeneration in the affected compartment [4-8]. Clinical improvement can be achieved by correcting the deformity and by reducing the tibiofemoral contact area. For medial compartment arthritis of the knee, open wedge high tibial osteotomy (OWHTO) is a well-known therapeutic option. This procedure provides the favourable mechanical environment for better healing of the articular cartilage by reducing the load on the involved compartment [14–15]. Therefore, the transfer of the weight-bearing axis into the lateral compartment leads to adequate unloading in the affected compartment and contribute to significant clinical improvement [16]. The long-term survival of HTO for medial OA has been reported to be between 56 and 79 percent [25–26].

Studies have shown that MMPHRT causes meniscal displacement, which weakens the properties of meniscus, worsening osteoarthritis [4, 5]. Various modalities of treatment have been tried for MMPHRT. At a 5-year follow-up, Krych et al found poor clinical outcome and increased risk of arthroplasty secondary to osteoarthritis following nonoperative treatment [27]. Studies have shown that the arthroscopic partial meniscectomy is associated with worsening of osteoarthritis [28]. At a mean follow-up of 77 months post partial meniscectomy, Han et al found that 16 of 46 patients [35%] had progressive degenerative arthritis, and only 56 percent of patients experienced clinical improvements. According to Chung et al refixation of the MMPHRT reduced the progression of osteoarthritis compared to partial meniscectomy [28,29].

MMPHRT repair improves meniscal hoop tension thereby suppress degeneration of meniscus [30]. Studies have shown concurrent root repair with HTO enhances healing of meniscus. It is important to reduce the extruded meniscus to restore the hoop tension which in turn contribute to meniscal healing [31]. Study done by Kim et al. has shown improved Outerbridge grades of femoral condyle of medial side after concurrent root repair with HTO [32]. Similarly, Lee et al. and Kee et al. have favourable medial compartment coverage after concurrent procedure [33]. However, Lee et al. reported no statistically significant intergroup difference of cartilage recovery when ICRS regeneration grading system was used [33].

Furthermore, following HTO alone, the rate of root healing was low and second-look arthroscopy data revealed the most healed MMPRTs exhibited healing with scars [34–35]. Our study showed clinical improvement similar to other studies and did not show any progression to further osteoarthritis.

However, the long-term results of combined procedure are unclear. Long term benefits of joint preservation surgery are

dependent on cartilage recovery and subsequent healing of MMPHRT. Few factors like low healing potential of degenerative tissues and meniscal extrusion are biomechanical factors impeding healing of the repaired MMPHRT. There are several studies which suggest futility of MMPHRT along with HTO. Currently, there is no consensus whether MMPHRT should be repaired or not along with HTO. Our consensus is to have advantage of repaired meniscus along with HTO for near normal biomechanics of knee to last for a longer time.

Our study has several limitations. The number of cases is limited, probably due to ongoing covid pandemic. Second look arthroscopy was not done to assess the cartilage status. Postoperative MRI could have been done to look for meniscal status post repair. Long term follow up is required to further assess for progression of osteoarthritis.

## References

- Fithian, D.C.; Kelly, M.A.; Mow, V.C. Material properties and structure-function relationships in the menisci. *Clin. Orthop. Relat. Res.* 1990;252, 19–31.
- Koenig, J.H.; Ranawat, A.S.; Umans, H.R.; Difelice, G.S. Meniscal root tears: Diagnosis and treatment. *Arthrosc. J. Arthrosc. Relat. Surg.* 2009, 25, 1025–1032.
- Kan, A.; Oshida, M.; Oshida, S.; Imada, M.; Nakagawa, T.; Okinaga, S. Anatomical significance of a posterior horn of medial meniscus: The relationship between its radial tear and cartilage degradation of joint surface. *Sports Med. Arthrosc. Rehabil. Ther. Technol.* 2010, 2, 1.
- Allaire R, Muriuki M, Gilbertson L, Harner CD. Biomechanical consequences of a tear of the posterior root of the medial meniscus. Similar to total meniscectomy. *J Bone Joint Surg Am.* 2008;90(9):1922–31.
- Marzo JM, Gurske-DePerio J. Effects of medial meniscus posterior horn avulsion and repair on tibiofemoral contact area and peak contact pressure with clinical implications. *Am J Sports Med.* 2009;37(1):124–9.
- Padalecki JR, Jansson KS, Smith SD, Dorman GJ, Pierce CM, Wijdicks CA, et al. Biomechanical consequences of a complete radial tear adjacent to the medial meniscus posterior root attachment site: in situ pull-out repair restores derangement of joint mechanics. *Am J Sports Med.* 2014;42(3):699–707.
- Jiang EX, Abouljoud MM, Everhart JS, DiBartola AC, Kaeding CC, Magnus sen RA, et al. Clinical factors associated with successful meniscal root repairs: a systematic review. *Knee.* 2019;26(2):285–91.
- Kim JH, Chung JH, Lee DH, Lee YS, Kim JR, Ryu KJ. Arthroscopic suture anchor repair versus pullout suture repair in posterior root tear of the medial meniscus: a prospective comparison study. *Arthroscopy.* 2011;27(12):1644–53.
- Kim SB, Ha JK, Lee SW, Kim DW, Shim JC, Kim JG, et al. Medial meniscus root tear refixation: comparison of clinical, radiologic, and arthroscopic findings with medial meniscectomy. *Arthroscopy.* 2011;27(3):346–54.
- Moon HK, Koh YG, Kim YC, Park YS, Jo SB, Kwon SK. Prognostic factors of arthroscopic pull-out repair for a posterior root tear of the medial meniscus. *Am J Sports Med.* 2012;40(5):1138–43.
- Moon HS, Choi CH, Jung M, Lee DY, Hong SP, Kim SH. Early surgical repair of medial meniscus posterior root tear minimizes the progression of meniscal extrusion: 2-year follow-up of clinical and radiographic parameters after arthroscopic transtibial pull-out repair. *Am J Sports Med.* 2020;48(11):2692–702.
- Chung KS, Ha JK, Ra HJ, Kim JG. Preoperative varus alignment and postoperative meniscus extrusion are the main long-term predictive factors of clinical failure of meniscal root repair. *Knee Surg Sports Traumatol Arthrosc.* 2021.
- Chung KS, Ha JK, Ra HJ, Kim JG (2016) Prognostic factors in the midterm results of pullout fixation for posterior root tears of the medial meniscus. *Arthroscopy.* 2016;32(7):1319–27.
- Bonasia DE, Dettoni F, Sito G, Blonna D, Marmotti A, Bruzzone M, et al. Medial opening wedge high tibial osteotomy for medial compartment overload/arthritis in the varus knee: prognostic factors. *Am J Sports Med.* 2014;42(3):69–78.
- Floerkemeier S, Staubli AE, Schroeter S, Goldhahn S, Lobenhofer P. Outcome after high tibial open-wedge osteotomy: a retrospective evaluation of 533 patients. *Knee Surg Sports Traumatol Arthrosc.* 2013;21(1):170–80.
- Ferruzzi A, Buda R, Cavallo M, Timoncini A, Natali S, Giannini S. Cartilage repair procedures associated with high tibial osteotomy in varus knees: clinical results at 11 years' follow-up. *Knee.* 2014;21(2):445–50.
- Birmingham TB, Moyer R, Leitch K, Chesworth B, Bryant D, Willits K, et al. Changes in biomechanical risk factors for knee osteoarthritis and their association with 5-year clinically important improvement after limb realignment surgery. *Osteoarthritis Cartilage.* 2017;25(12):1999–2006.
- Bin SI, Kim JM, Shin SJ. Radial tears of the posterior horn of the medial meniscus. *Arthroscopy.* 2004;20(04):373–378
- Robertson DD, Armfield DR, Towers JD, Irrgang JJ, Maloney WJ, Harner CD. Meniscal root injury and spontaneous osteonecrosis of the knee: an observation. *J Bone Joint Surg Br* 2009;91(02): 190–195
- Jung WH, Takeuchi R, Chun CW, Lee JS, Ha JH, Kim JH, et al. Second-

- look arthroscopic assessment of cartilage regeneration after medial opening wedge high tibial osteotomy. *Arthroscopy*. 2014;30(1):72–9.
21. Sterett WI, Steadman JR, Huang MJ, Matheny LM, Briggs KK. Chondral resurfacing and high tibial osteotomy in the varus knee: survivorship analysis. *Am J Sports Med*. 2010;38(7):1420–4.
  22. Kim KI, Seo MC, Song SJ, Bae DK, Kim DH, Lee SH. Change of chondral lesions and predictive factors after medial open-wedge high tibial osteotomy with a locked plate system. *Am J Sports Med*. 2017;45(7):1615–21.
  23. Jung WH, Takeuchi R, Chun CW, Lee JS, Jeong JH. Comparison of results of medial opening-wedge high tibial osteotomy with and without sub chondral drilling. *Arthroscopy*. 2015;31(4):673–9.
  24. Wakabayashi S, Akizuki S, Takizawa T, Yasukawa Y. A comparison of the healing potential of fibrillated cartilage versus eburnated bone in osteoarthritic knees after high tibial osteotomy: an arthroscopic study with 1-year follow-up. *Arthroscopy*. 2002;18(3):272–8.
  25. LaPrade RF, Ho CP, James E, Crespo B, LaPrade CM, Matheny LM. Diagnostic accuracy of 3.0 T magnetic resonance imaging for the detection of meniscus posterior root pathology. *Knee Surg Sports Traumatol Arthrosc* 2015;23(01):152–157
  26. Lee DW, Kim MK, Jang HS, Ha JK, Kim JG. Clinical and radiologic evaluation of arthroscopic medial meniscus root tear re-fixation: comparison of the modified Mason-Allen stitch and simple stitches. *Arthroscopy* 2014;30(11):1439–1446
  27. Krych AJ, Reardon PJ, Johnson NR, et al. Non-operative management of medial meniscus posterior horn root tears is associated with worsening arthritis and poor clinical outcome at 5-year follow-up. *Knee Surg Sports Traumatol Arthrosc* 2017;25(02): 383–389
  28. Chung KS, Ha JK, Yeom CH, et al. Comparison of clinical and radiologic results between partial meniscectomy and re-fixation of medial meniscus posterior root tears: a minimum 5-year follow-up. *Arthroscopy* 2015;31(10):1941–1950
  29. Han SB, Shetty GM, Lee DH, et al. Unfavorable results of partial meniscectomy for complete posterior medial meniscus root tear with early osteoarthritis: a 5- to 8-year follow-up study. *Arthroscopy* 2010;26(10):1326–133
  30. Okazaki Y, Furumatsu T, Masuda S, Miyazawa S, Kodama Y, Kamatsuki Y, et al. Pullout repair of the medial meniscus posterior root tear reduces proton density-weighted imaging signal intensity of the medial meniscus. *Acta Med Okayama*. 2018;72(5):493–8.
  31. LaPrade CM, Foad A, Smith SD, Turnbull TL, Dornan GJ, Engebretsen L, et al. Biomechanical consequences of a nonanatomic posterior medial meniscal root repair. *Am J Sports Med*. 2015;3(4):912–20.
  32. Kim YM, Joo BY, Lee WY, Kim YK. Remodified Mason-Allen suture technique concomitant with high tibial osteotomy for medial meniscus posterior root tears improved the healing of the repaired root and suppressed osteoarthritis progression. *Knee Surg Sports Traumatol Arthrosc*. 2020.
  33. Lee DW, Lee SH, Kim JG. Outcomes of medial meniscal posterior root repair during proximal tibial osteotomy. Is root repair beneficial? *Arthroscopy*. 2020.
  34. Kodama Y, Furumatsu T, Fujii M, Tanaka T, Miyazawa S, Ozaki T. Pullout repair of a medial meniscus posterior root tear using a FasT-Fix all-inside suture technique. *Orthop Traumatol Surg Res* 2016;102(07):951–954
  35. Chung KS, Ha JK, Ra HJ, Nam GW, Kim JG. Pullout fixation of posterior medial meniscus root tears: correlation between meniscus extrusion and midterm clinical results. *Am J Sports Med* 2017;45(01):42–49

**Declaration of patient consent:** The authors certify that they have obtained all appropriate patient consent forms. In the form, the patient has given his consent for his images and other clinical information to be reported in the Journal. The patient understands that his name and initials will not be published, and due efforts will be made to conceal his identity, but anonymity cannot be guaranteed.

**Conflict of interest:** Nil **Source of support:** None

### How to Cite this Article

Pilar A, Madan MM, Sunil LK, Babu SS, Sekaran P, Amaravathi RS | Functional Outcome Following Concurrent Medial Meniscus Posterior Horn Root Repair during High Tibial Osteotomy in Early Medial Compartment Osteoarthritis | *Journal of Karnataka Orthopaedic Association* | January-February 2022; 10(1): 09-14.