



RESEARCH ARTICLE

A RARE CASE OF LARGE PARAVAGINAL CYST

Dr. Suryaprabha, V.¹, Dr. Ram Chandra², Dr. Ram Kumar³ and Dr. Daisy Prabhu⁴

¹Professor and Head of the Department of Obstetrics & Gynaecology, Visakhapatnam District, Andhra Pradesh

^{2,3}Associate Professor, Department of General surgery Visakhapatnam District, Andhra Pradesh

⁴Assistant Professors, NRI Hospital Sangivalasa, Visakhapatnam District, Andhra Pradesh

ARTICLE INFO

Article History:

Received 15th March, 2021

Received in revised form

24th April, 2021

Accepted 19th May, 2021

Published online 30th June, 2021

Keywords:

Vaginal cyst, Rare, cyst.

ABSTRACT

A 44-year reproductive age woman came to outpatient Department of Gynaecology, Anil Neerukonda Hospital with complaints of excessive bleeding (Menorrhagia) and abdominal pain. Evaluation and Treatment of Cystic lesions which are often encountered and rarely diagnosed in Urogynecological practice. This is a rare case and will be confused with other cysts like Retrorectal cyst¹², Tailgut duplication cyst or Cyst arising from anterior wall of rectum and also Gynaecological cysts like Gartner's cyst¹, Paravaginal Dermoid cyst¹⁰ and Retention cysts like Epidermoid Cysts and Squamous inclusion cyst. Cystic lesion of vagina are benign. Mostly they may have embryological origin, Ectopic tissue or Neurological abnormality. Awareness of these conditions is very important for diagnosis and treatment. While these lesions may be detected on ultrasound (US), Computed tomography (CT), or MRI. MRI has superior contrast resolution and allows for distinction between the various types of cysts, with location being the most important discriminating factor (Anuj Gupta, D.O., James E. Kovacs, D.O.). In females, the diverticula commonly extend from the posterolateral wall of the mid-portion of the short female urethra. During voiding cystourethrography (VCUG), they are best portrayed on post void images. On transrectal or transperineal US, a cystic mass with complex fluid in proximity to the urethra will be seen anterior to the vaginal wall. Trans perineal US may be useful as an initial diagnostic examination tool; however, transrectal US will have greater specificity for small diverticula. Advantages of US over CT include better localization, lack of radiation, and capacity to differentiate solid from cystic masses. CT will demonstrate a periurethral lesion with low attenuation. On MRI, urethral diverticula will contain T1 hypo intense and T2 hyperintense fluid signal intensity. Postcontrast imaging with Gadolinium can be used to evaluate for infection or inflammation. To differentiate and diagnose the origin of mass above investigations are necessary as mentioned in above articles. The main aim of presenting this case is of its size which occupying below from vulvar outlet to 1 inch above the vault and laterally complete left lateral wall clinically. On clinical examination and examination under anaesthesia the upper border of the mass could not be felt causing clinical dilemma. The radiological imaging by Ultrasonography could not throw much light regarding type location and origin of mass. MRI was done to know the plane of mass. As patient had abnormal uterine bleeding and mass is very big up to vault planned for surgery by abdominal pelvic approach. Total abdominal hysterectomy was done, ovaries left behind as they are healthy. Cyst excised through vaginal route and sent for histopathology.

INTRODUCTION

Inclusion cyst is mainly seen in the lower end of the vagina on its posterior surface and is caused by tags of mucosa embedding inside the scar that later forms a cyst. (Shaw's text book of Gynaecology) The most common type of cyst is the vaginal inclusion cyst, or an epithelial inclusion cyst is also referred to as epidermal inclusion cyst or squamous epithelium inclusion cyst. This type of cyst comprises 23% of all vaginal cysts and is very common. This cyst originates from epithelium tissue that has been "trapped" from surgery, episiotomy, or other trauma.

It is most often found on the lower posterior vaginal wall. An epidermoid cyst is one type of vaginal cyst. Inclusion cysts are small and located on the posterior, lower end of the vagina. Paravaginal cysts are relatively infrequent developmental anomalies. Mostly the Gartner's cysts are found, which arise from the remnants of the Gartner's duct. These cysts are often accompanied by other developmental anomalies of the urogenital and genital tract. Paravaginal cyst³ is a rare entity in gynaecological practice. This is simple cyst arising from anterolateral aspect of the superior vagina. There are Gartner's cysts with varying sizes. Deppish¹¹ in 1975 described 25 cases of symptomatic vaginal cysts. They reported a wide range of symptoms which include dyspareunia, vaginal pain, difficulty in tampon use, urinary symptoms and palpable mass. In the

*Corresponding author: Dr. Suryaprabha, V.

Professor and Head of the Department of Obstetrics & Gynaecology

literature, one case of double gartner's duct cyst is described. Clinically it is very difficult to differentiate Gartner's cyst, Para vaginal dermoid cyst¹⁰. Inclusion cyst and cyst arising from surrounding tissues like cervical cyst, Nabothian cyst, Retrorectal cyst, Tail gut duplication cyst¹²etc. The case which we presented here is a larger vaginal cyst which can be confused with large Gartner's cyst clinically which was published in the past.

CASE REPORT

A 44 year old Para 2, Live 2 presented to Anil Neerukonda hospital on 7/6/2021 with complaints of menorrhagic cycles since 2 months, associated with pain, changing 4- 5 pads per day, not associated with clots, and foul smelling discharge. H/o dyspareunia due to which she was in abstinence for the last six months. No H/o bowel disturbances. No H/o fever, no white discharge, no burning micturition, no loss of appetite and weight. Last menstrual period- 1/06/2021, Previous menstrual history- regular, 3-4/30 days, not associated with pain and clots. Marital life- 30yrs, Non consanguineous Pare 2, Live 2- first delivery- normal vaginal delivery , second delivery- Caesarean section- Indication- Big baby , last child birth- 24 yrs. No history of similar complaints in the past. Known case of Diabetes for the last 3 years, on T. METFORMIN 500mg twice daily. Not a known case of Hypertension, Tuberculosis, Bronchial asthma, Epilepsy, no history of Thyroid dysfunction. No history of similar complaints in family.

On examination: Patient is moderately built, conscious, coherent, no pallor, no icterus, no cyanosis, no clubbing, no lymphadenopathy, no pedal oedema. Pulse rate- 80 per minute, regular, normal volume, Blood pressure-120/80 mmHg in supine position, Thyroid- normal, Bilateral breast- normal, Spine- normal.

PER ABDOMEN

On Inspection: Thick anterior abdominal wall, skin over the abdomen normal, Umbilicus inverted, midline, all quadrants moving equally with respiration. Sub-umbilical mid line thin vertical scar present, no keloid, healed by primary intention no sinuses, hernia sites free. No engorged veins, Striae gravidarum present.

Palpation: Soft, no palpable masses, no lymphadenopathy and no fluid thrill.

Percussion: Resonant, no shifting dullness noted.

Per speculum: Fullness of posterior vaginal wall on left side of vagina was noted, uterus and cervix drawn up and could not be visualized.

Per vaginal examination: A soft mass extending from left lateral wall to right lateral wall with gap of 2-3 fingers was felt, upper border could not be reached and was occupying left lateral wall and lower border was almost up to fourchette. Cervix and uterus pulled up and could not be felt. Right fornix free. No mass felt in Pouch of Douglas.

Per Rectal examination: Felt a soft mass through anterior wall of rectum, rectal mucosa freely mobile on the mass. No nodularity, No bleeding on examination finger.

INVESTIGATIONS

Haemoglobin - 10.9 gm.%, RBC- 4.3 million/mm³, WBC- 12,400 cells/mm³, Blood grouping and typing- O+VE, Serology- NEGATIVE, Serum Creatinine -0.6 mg/dl, Random blood sugars - 266mg/dl, HbA1C- 6.7 %.

Ultrasonography: A well-defined cystic lesion measuring 14x8 cm noted posterior to cervix and vagina and the cyst shows internal echoes (Fig 1, 1a) by Dr. Pradeep

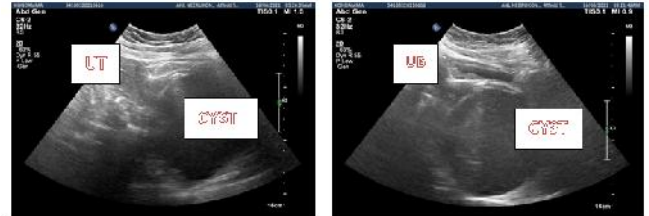
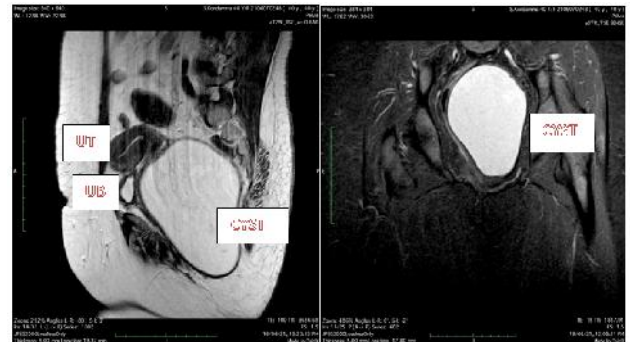

Fig -1 ,1a

MRI pelvis: well defined thick walled cystic lesion with heterogeneous contents measuring 14x 10.6 x 13 cm in left posterior and lateral aspect of rectum and posterior to cervix and vagina. With differential diagnosis of Tail gut cyst or Gartner's cyst or Inclusion cyst. FIG 2&2A---by Dr. Pradeep-



MRI FIG 2&2A

Patient was admitted on 17/06/2021 .After achieving Glycaemic control posted for surgery. As there is a possibility of cyst arising from rectum or retroperitoneal area second opinion was taken from Surgeon and then posted for exploratory laparotomy in association with General surgeon.

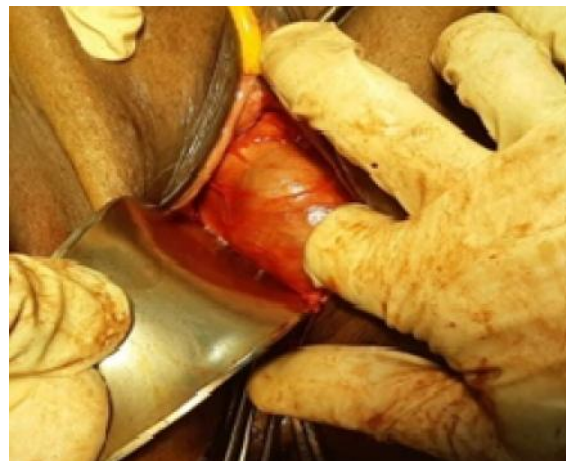

Fig-3 Vaginal cyst

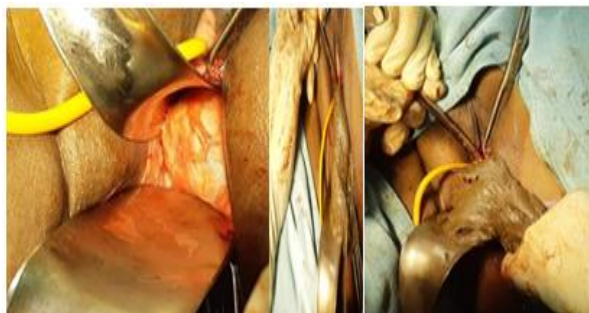


Fig. 4. Pultaceous material

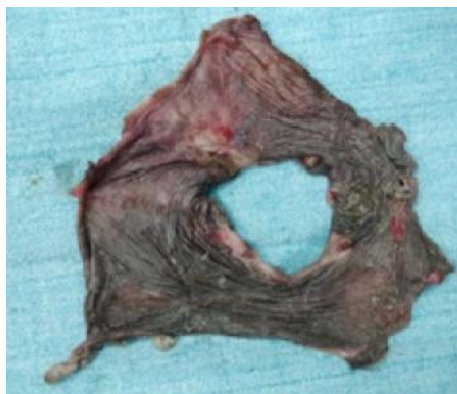

Fig. 5. Cyst wall

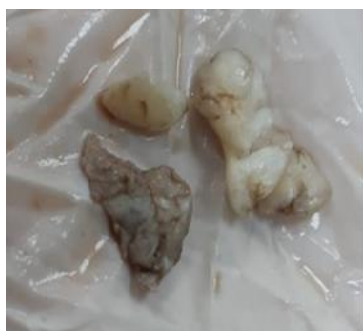

Fig. 6. Contents of mass

Surgical procedure

Explorative Laparotomy + Total Abdominal Hysterectomy + Vaginal Cystectomy.

Incision: Left paramedian incision extending 2 – 2 1/2 inches above the umbilicus. Before opening of abdomen, per vaginal examination is done under anaesthesia and upper border of the mass could be felt with difficulty near the vault pushing it to abdomen which is merging into left lateral wall of pelvis. Abdomen opened in layers.

Intraoperative finding: Peritoneal cavity opened, 1) uterus, ovaries and fallopian tubes are normal no mass is felt in the parametrium, lateral walls of pelvis. 2) The mass felt vaginally couldn't be felt abdominally either in Pouch of Douglas or in the lateral parametrium. Flimsy adhesions released between Infundibulopelvic ligament and bowel. 3) Left paracolic gutter opened and given access to Retroperitoneum, cyst could not be felt after reflection of left colon. Decision was taken to approach the cyst through vault. As patient is having Abnormal uterine bleeding proceeded with Total abdominal hysterectomy (TAH), uterus along with the cervix is removed and sent for

Histo- pathological examination. Tried to hold the upper part of the cyst through opening in vault abdominally but couldn't make a opening in the cyst. Then approached vaginally. A transverse incision over posterior vaginal wall over mass was given then cyst is identified which is about 10 x 12cms size. Cyst wall is incised, pultaceous material with white plaques was drained. Intraoperatively thought of Inclusion cyst or dermoid macroscopically. After through wash with Betadine and Hydrogen peroxide Cyst wall was excised. Abgel and Corrugate drain is kept in-situ and posterior vaginal wall was closed with Chromic catgut 1-0. Pultaceous material and cyst wall is sent for Histopathological examination. Per rectal examination is done and rectal mucosal was intact. Abdominally vaginal vault was closed with continuous sutures with No:1 Vicryl. Haemostasis secured. Mops and instruments verified. Saline abdominal wash given and abdominal drain was kept in situ. Rectus sheath closed with loop Nylon. Skin is closed with Nylon mattress sutures. Betadine vaginal packing done. Intra operative and immediate post operative period uneventful. Post operative period: Vaginal pack removed on 1st post operative day. Abdominal drain, vaginal drain removed on 2nd Post operative day. Two units of blood transfusion done on 1st and 5th Post operative days. Regular dressing done and suture removal done on 11th post operative day. Postoperative period uneventful. Patient got discharged on 12th post operative day.

Histopathology Report

Cyst: Sections showed cyst wall lined by Keratinised Stratified Squamous epithelium. Cyst wall formed by fibrous tissue with focal areas showing skeletal muscle fibres admixed with mild mononuclear inflammatory cell infiltrate. Cyst lumen filled with lamellate keratin.

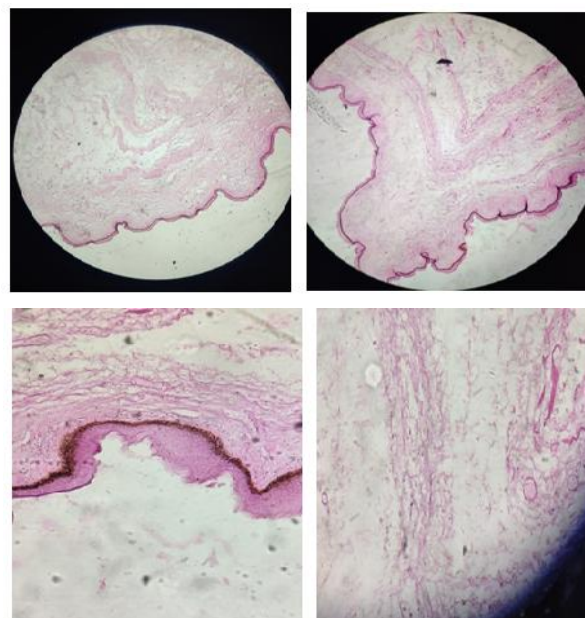


Fig. 7. Cyst wall HPE

Endometrium: Section studied shows round to oval endometrial glands lined by Columnar epithelium with compact stroma.

Myometrium: Sections studied show smooth muscle fibres in interlacing fascicles.

Cervix: Section studied show ectocervix and endocervix, sub epithelium showing fibro collagenous tissue with endocervical glands and variable sized blood vessels.

Impression: Cyst- Squamous Inclusion Cyst; Endometrium-Late proliferative phase Myometrium- Nil particular; Cervix- Chronic cervicitis.

Acknowledgments

1)Department of Radiology -Dr. Pradeep Tavva, Assistant professor. 2)Department of Anesthesia-Dr. Zohra, Associate professor, Dr.Padmalata, Assistant professor. 3)Department of Pathology - Dr. Navaneetha Nath, professor and HOD. 4)Department of Obstetrics and Gynaecology- Dr. N. Lalitha Bhavani, Dr. Y.L.Aparna..

REFERENCES

- Asian Journal of Science and Technology Vol. 08, Issue, 12, pp.7137-7139, December, 2017 Research article Management of a Big Gartner's Cyst 1Dr. Krishnamma, B. S. and 2Dr. Suryaprabha.V
- Sharma R, Rao KA, Nagraj S. A rare case of vaginal dermoid cyst: a case report and review of literature. *Int J Infert Fetal Med.* 2012;3:102-4.
- Stokes JE, Rep JH. The etiology and structure of true vaginal cysts. *Johns Hopkins Hosp Rep.* 1899;7:109- 36.
- Siu SS, Tam WH, To KF, Yuen PM. Is vaginal dermoid cyst a rare occurrence or a misnomer? A case report and review of the literature. *Ultrasound Obstet Gynecol: Official J Int Soc Ultrasound Obstet Gynecol.* 2003;21(4):404-6.
- Fujita K, A Kiyama N, Ishizaki M, Taraka S, Ohsawa K, Sugiyama H, *et al.* Dermoid cyst of colon. *Dig Surg.* 2001;18:335-7.
- Longo F, Moremonti P, Mangone GM, DeMaria G, Califano L. Midline dermoid cyst of the floor of the mouth: Report of 16 cases and review of surgical techniques. *Plast Reconstr Surg.* 2003;112:1560-5.
- Schuetz MJ 3rd, Elsheikh TM. Dermoid cyst (mature cystic teratoma) of the caecum. Histologic and cytologic features with review of the literature. *Arch Pathol Lab Med.* 2002;126:97-9.
- Curtis AH. Transaction of societies: Chicago Gynecological Society. *Surg Gynecol Obstet.* 1913;16:715.
- Johnston HW. A dermoid cyst of the vagina complicated by pregnancy. *Canad Med Ass J.*1939;41(4):386.
- Hirose R, Imai A, Kondo H, Itoh K, Tamaya T. A dermoid cyst of the paravaginal space. *Archynecal Obstet.*1991;249:39-41.
- Deppisch LM. 1975. Cysts of the vagina. *Obstet Gynaecol.*, 45:632-7.
- Lukanovic A, Patrelli TS. 2010. Retroperitoneal mass with ischiorectal fossa extension: diagnosis, clinical features and surgical approach. A literature review starting from a rare clinical care of primary retroperitoneal dermoid cyst. *Europ J Gynaecol Oncol.*,31(6):709-3.
- Al-Shahrani MS, Heywood M. 2006. A rare case of vaginal dermoid cyst: A case report and review of literature. *Biomed Res.*, 17(2).
