



RIDGE AUGMENTATION USING AUTOGENOUS BONE GRAFT FOR IMPLANT SITE DEVELOPMENT

Dr Deepthi V^{1*}, Dr Indu V², Dr Baiju R M³, Dr Ankitha K⁴, Dr Nadeem AbdulRahman⁵

^{1*} Assistant Professor, Dept. Of Periodontics, Kannur Dental College, Anjarakkandy P.O Kannur, Kerala. Nandanam, P.O. Chala East, Kannur, Kerala PIN – 670621, Email id : deepv32@gmail.com
ORCID ID : 0000-0003-3120-8843

²Dental Surgeon, Doctor s dental care, Changanassery Kottayam ,Kerala.

³Additional Professor, Dept. Of Periodontics, Govt. Dental College, Kottayam ,Kerala ⁴Reader , Dept. Of Prosthodontics, Kannur Dental College, Anjarakkandy P.O Kannur, Kerala. ⁵Reader , Dept. Of Prosthodontics, Kannur Dental College, Anjarakkandy P.O Kannur, Kerala.

***Corresponding Author:** Dr Deepthi V(MDS)

*Assistant Professor, Dept. Of Periodontics, Kannur Dental College, Anjarakkandy P.O Kannur, Kerala. Nandanam, P.O. Chala East, Kannur, Kerala PIN – 670621, Email id : deepv32@gmail.com
ORCID ID : 0000-0003-3120-8843

Abstract :

Successful placement of dental implants requires a minimum amount of bone both in width and height at the recipient site to provide a functional and esthetic implant-borne restoration for the patient. But patients often present for implant placement after a certain period of edentulousness and subsequent ridge resorption. In such cases ridge augmentation procedures become the most promising option to both the patient and the clinician. This case report describes ridge augmentation using Autogenous Block Graft harvested from the mandibular symphysis region and subsequent implant placement for a young patient.

Keywords: Ridge Augmentation, Autogenous Bone Graft, Block graft, Implants, Piezosurgery

Background

Dental implants are currently a dependable solution for restoring dental function in patients with missing teeth.^[1] Having a sufficient amount of alveolar bone and ideal conditions in the soft tissues are crucial for achieving successful results with dental implants, particularly in areas that are aesthetically significant.^[2] However, unfavorable local conditions of the alveolar ridge as a result of atrophy, periodontal disease, and injuries, puts the clinician in challenging situations while placing implants. There are five primary techniques that have been identified for bone augmentation: (1) osteo induction with the use of appropriate growth factors (2) osteo conduction, wherein the graft material acts as a scaffold for new bone formation (3) distraction osteogenesis, which involves intentionally creating a fracture and gradually separating the two pieces of bone, which promotes the growth of new bone tissue between them (4) guided bone regeneration (GBR), which places barrier membranes to create space for bone fill and (5) revascularized bone grafts, which involves transferring a vital bone segment, along with its blood supply, to the recipient area thereby enabling the bone to survive

immediately without requiring any remodeling or substitution.^[1] This article presents a case report of alveolar ridge augmentation with autogenous bone block procured from the mandibular symphysis region using piezosurgery and delayed implant placement in relation to 21.

Case description

An 18-year-old male patient visited the Periodontics department at Govt. Dental College, Kottayam with a missing tooth in the upper front region and gave a history of trauma 4 days back following which he lost the tooth. On clinical examination 21 was missing, and 11 and 22 were having an Ellis class I fracture. Also a wire and composite splint was in place at the time of examination. Various treatment options were explained of which they opted for an implant supported restoration. Bone mapping was done under LA which revealed a deficiency in the width of alveolar bone with only 2mm (Class IV ridge defect)^[3] in the coronal most aspect (Fig . 1 , 2). A cone beam computed tomography (CBCT) was taken which confirmed the horizontal deficiency in need of bone augmentation procedures.

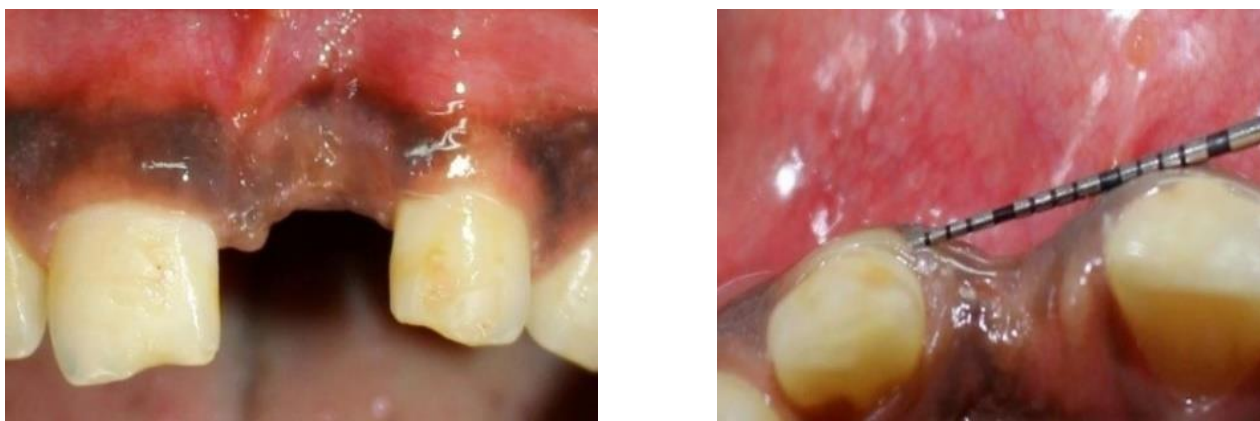


Fig . 1,2 Pre operative clinical photograph demonstrating deficient ridge

Mandibular symphysis was chosen as the donor site. The surgical procedure was carried out under local anaesthesia. The donor site was exposed with a horizontal incision in the attached gingiva in relation to 31, 32, 33. The osteotomies were performed using piezo surgery unit (Acteon). The two horizontal cuts were performed first followed by the vertical cuts and the bone block was gently lifted using a chisel and mallet. Abgel was used to achieve hemostasis and 5-0 vicryl was used for subcutaneous closure of the wound followed by 3-0 silk on the external surface (Fig. 3 to 5). A crestal incision and two vertical releasing incisions were given and a full thickness mucoperiosteal flap was elevated to expose the ridge defect at the recipient site. Decortication of the recipient site was done to enhance revascularization of the graft. The procured graft was contoured for proper incorporation into the defect. A hole was drilled through the graft for placing the fixation screw. A 2 mm diameter and 10 mm length titanium screw was utilized to secure the graft. Osseograft along with autogenous graft particles collected during contouring of the block graft were used to fill the gaps and to cover the dehiscence in relation to buccal aspect of 22. A bioresorbable membrane (Healiguide) was used to cover the graft. Periosteal releasing incisions were given to mobilize the flap and achieve primary closure (Fig 6,7). Post operative antibiotics and analgesics were given for 7 days. Postoperative healing period was uneventful and the patient was kept on regular maintenance care.

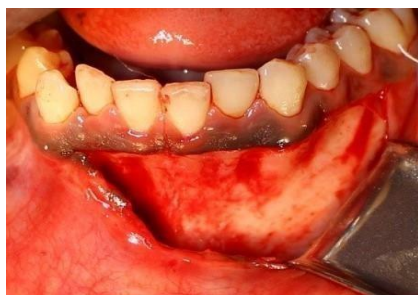

Fig. 3 Donor site flap reflection

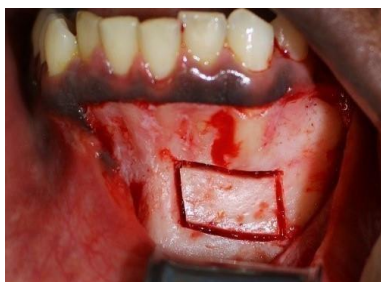

Fig. 4 Donor site outlined for block graft harvesting

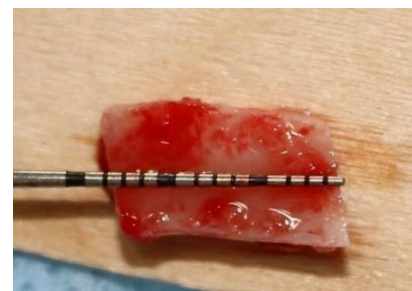

Fig. 5 Dimensions of the harvested block graft

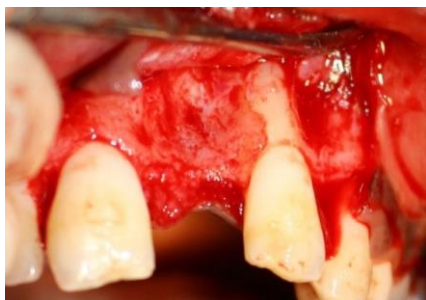

Fig. 6 Receptient site flap reflection

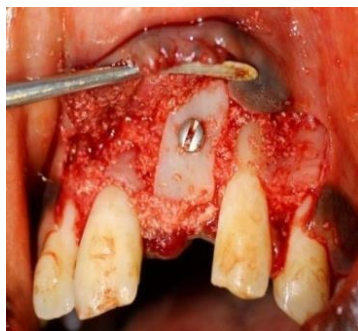

Fig. 7 Graft secured with screws

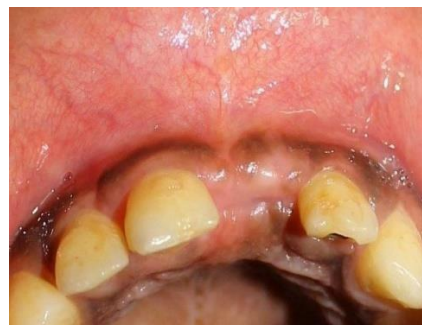

Fig. 8 Post operative 6 months view showing gain in ridge width

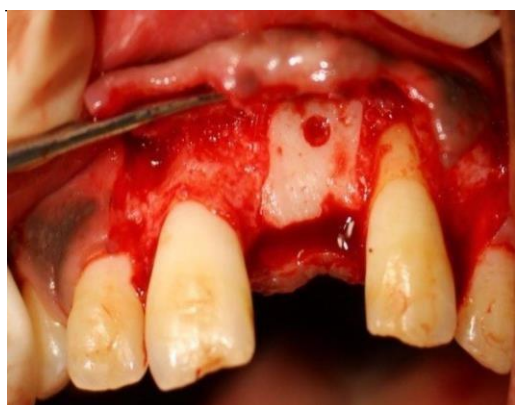

Fig. 9 Surgical site re entered and fixation screw removed

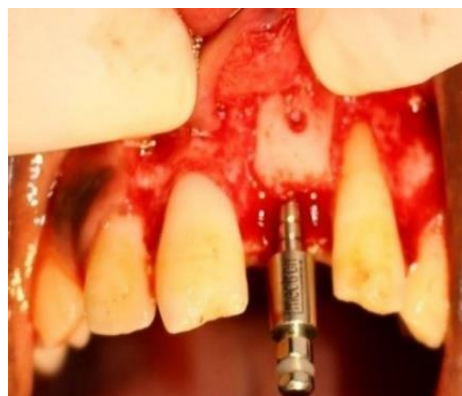

Fig. 10 Ridge expansion

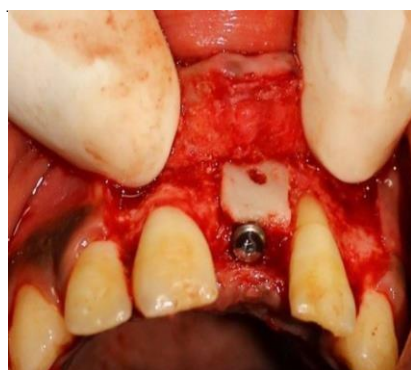

Fig. 11 Implant placed

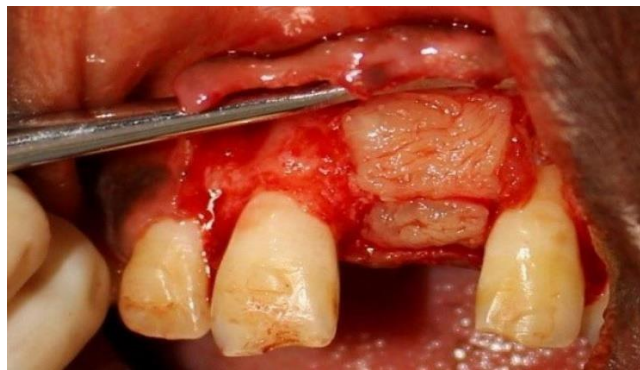

Fig. 12 Bone graft and PRF

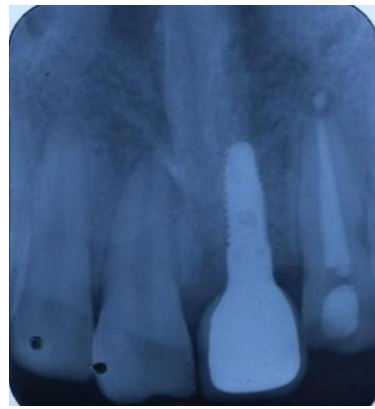
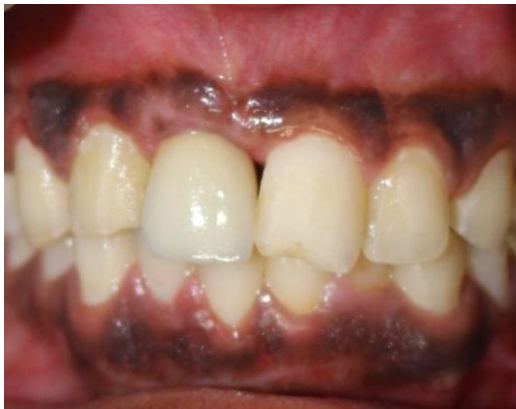
Fig.13,14 Clinical and radiographic image after crown placement

The surgical site was re entered after 6 months for implant placement (Fig.8). Local anaesthesia was given and a mid crestal and two releasing incisions were given to expose the surgical site. There was minimal resorption around the graft and the post surgical alveolar width was measured to be 4.5mm. The stabilizing screw was removed and the graft had good stability. A 3.3 X 13 mm Global Medical Implants (GMI) implant was planned for the site and hence a ridge split had to be carried out. The implant was placed with good initial stability. Osseo graft was used to cover the screw hole and a platelet rich fibrin (PRF) membrane was placed. The surgical site was closed with 3-0 silk. Post operative antibiotics and analgesics were given (Fig.9 to 12). Second stage surgery was carried out after 6 months and healing abutment was placed. 2 weeks later impressions were taken and the implant crown was made (Fig. 13,14).

Discussion

Among the various bone grafts for augmentation, autogenous bone is thought to be the best option as it is osteoconductive, osteo inductive and osteogenic.^[4] Extra oral donor sites for autogenous bone grafts include iliac crest, calvarium, rib, and tibia. Intra orally autogenous bone can be harvested from mandibular ramus, mandibular symphysis, angle of mandible, maxillary tuberosity and bony exostoses.^[5] Among all the intraoral sites, mandibular symphysis region offers a large amount of cortico-cancellous autograft and easy surgical access.^[6] Therefore block grafts harvested from the symphysis can be used for predictable bone augmentation of up to 6 mm in horizontal and vertical dimensions with a thickness of 3 to 11 mm (most sites providing 5 to 8 mm). The density of the grafts is D-1 or D-2, and up to a three tooth edentulous site can be grafted.^[7] Surgical approach to the site can be through vestibular/alveolar mucosa incision, sulcular incision, submarginal/attached gingival incision or crestal incision in case of edentulous sites. In this case a submarginal incision was given which facilitates flap closure and avoids wound dehiscence.^[8] To initiate the bone cut the safety margins proposed by Pommer *et al.*^[9] in 2008 i.e depth of the bone graft should be 4 mm and the distance to the tooth apices should be kept at least 8 mm, the lower border should be kept intact with the 5 mm safety distance from the mental foramen was considered. Piezosurgery^[10] was used for bone harvesting as it offers considerable precision and enhanced operating sensitivity during surgery which allows to preserve the integrity of vital structures.

Summary

With the present concept of prosthetically driven implant dentistry, the number, size and the ideal implant position is determined by the final prosthesis. Implants placed without regard for prosthetic position often lead to dental restorations that are functionally and esthetically compromised. In this clinical case report avulsion of 21 as a result of trauma resulted in a localized alveolar ridge defect. Autogenous bone block harvested from the symphysis using piezosurgery facilitated rehabilitation of the lost tooth with implant supported prosthesis.

Declaration of patient consent

The patient has given his/her consent for his/her images and other clinical information to be reported in the journal. He/she have understood that their names and initials will not be published and due efforts will be made to conceal their identity in any form.

Financial support Nil.

Conflicts of interest

There are no conflicts of interest.

References:

1. Chiapasco M, Casentini P. Horizontal bone-augmentation procedures in implant dentistry: prosthetically guided regeneration. *Periodontology 2000* 2018;77:213-240.
2. Buser D, Belser U, Wismeijer D, dos Santos Jr J, Laney WR. ITI treatment guide, Vol. I: Implant therapy in the esthetic zone for single-tooth replacements. Chicago: Quintessence 2006.
3. Tolstunov L. Classification of the alveolar ridge width: Implant-driven treatment considerations for the horizontally deficient alveolar ridges. *The Journal of oral implantology* 2014;40 Spec No:365-370.
4. Carranza F. A. Newman M. G. Takei H. H. & Klokkevold P. R. Carranza's clinical periodontology 10th ed. Saunders Elsevier 2006.
5. D'addona A, Nowzari H. Intramembranous autogenous osseous transplants in aesthetic treatment of alveolar atrophy. *Periodontology 2000* 2001;27:148 161.
6. Hunt DR, Jovanovic SA. Autogenous bone harvesting: a chin graft technique for particulate and monocortical bone blocks. *International Journal of Periodontics & Restorative Dentistry* 1999;19.
7. Pikos MA. Mandibular block autografts for alveolar ridge augmentation. *Atlas of the oral and maxillofacial surgery clinics of North America* 2005;13:91-107.
8. Schuler R, Verardi S. A new incision design for mandibular symphysis bone-grafting procedures. *Journal of periodontology* 2005;76:845-849.
9. Pommer B, Tepper G, Gahleitner A, Zechner W, Watzek G. New safety margins for chin bone harvesting based on the course of the mandibular incisive canal in CT. *Clinical oral implants research* 2008;19:1312-1316.
10. Vercellotti T. Technological characteristics and clinical indications of piezoelectric bone surgery. *Minerva stomatologica* 2004;53:207-214.