

Gelatin Sponge-induced Early Onset Quadriplegia after the Posterior Decompression for Cervical Myelopathy Due to Ossification of a Posterior Longitudinal Ligament - A Case Report

Arulkumar Nallakumarasamy¹, Mantu Jain¹, Sibasish Panigrahi¹, Auroshish Sahoo¹, Suprava Naik²

Learning Point of the Article:

The iatrogenic gel foam-induced early onset postoperative neurological deterioration is very debilitating, the surgeons should be more vigilant in preventing and managing it accordingly.

The occurrence of postoperative neurological deterioration in patients with OPLL-induced cervical myelopathy who underwent posterior decompression is well established. However, the rare cause of early onset cord compression due to adsorbed gelatin sponge has to be considered when other common causes are ruled out. Although it is difficult to diagnose, the early suspicion and the management of such a condition are crucial to regaining the neurological function of the patient.

Abstract

Background: Gelatin foam has been regularly used in the complex neuro and spinal surgeries for a long time. Apart from their hemostatic properties, these are inert and provide form an inert membrane that prevents scar adhesions of vital structures such as the brain or spinal cord.

Case Presentation: We present a case of cervical myelopathy due to an ossified posterior longitudinal ligament that underwent the instrumented posterior decompression and had neurological worsening 48 h after the index surgery. An magnetic resonance imaging showed a hematoma compressing the spinal cord which on exploration was confirmed to be a gelatin sponge. It represents the rare phenomenon of mass effect due to their osmotic properties, especially in a closed space causing neurologic deterioration.

Conclusion: We emphasize the rare cause of early onset quadriplegia after the posterior decompression due to the swollen gelatin sponge over the neural elements. The patient recovered with timely intervention.

Keywords: Cervical myelopathy, ossification of posterior longitudinal ligament, gelatin sponge, early onset post-operative neurological deterioration, case report.

Introduction

Ossification of the posterior longitudinal ligament (OPLL) is routinely treated with indirect decompression by posterior laminectomy ± fusion. The procedure is comparatively effective and safer than the anterior approach when the spinal canal occupancy ratio is <50–60% [1]. However, there can be considerable blood loss from the epidural vein and bleeding raw bones, and surgeons have been using absorbable gelatins as a hemostat and effective interposing membrane over the naked

spinal cord to prevent scar adhesions. These gelatins can be counterproductive, and there are few reports of complications due to their usage in the literature [2, 3, 4, 5, 6].

Here, we report a patient with cervical OPLL who underwent a routine post-instrumented decompression but deteriorated in the early post-operative period. A magnetic resonance imaging (MRI) confirmed compression by tamponade effect of gelatin sponge which was subsequently revised. The patient showed improvement.

Author's Photo Gallery



Dr. Arunkumar Nallakumarasamy



Dr. Mantu Jain



Dr. Sibasish Panigrahi



Dr. Auroshish Sahoo



Dr. Suprava Naik

Access this article online

Website:
www.jocr.co.in

DOI:
10.13107/jocr.2022.v12.i06.2870

¹Department of Orthopaedics, All India Institute of Medical Sciences, Bhubaneswar, Odisha, India – 751019.

²Department of Radiodiagnosis, All India Institute of Medical Sciences, Bhubaneswar, Odisha, India – 751019.

Address of Correspondence:

Dr. Arulkumar Nallakumarasamy
Senior Resident, Department of Orthopaedics,
All India Institute of Medical Sciences, Bhubaneswar, Odisha, India – 751019
E-mail: arulmmcian@gmail.com

Submitted: 10/12/2021; Review: 15/02/2022; Accepted: May 2022; Published: June 2022

DOI:10.13107/jocr.2022.v12.i06.2870

This is an open access journal, and articles are distributed under the terms of the Creative Commons Attribution-NonCommercial-ShareAlike 4.0 License <https://creativecommons.org/licenses/by-nc-sa/4.0/>, which allows others to remix, tweak, and build upon the work non-commercially, as long as appropriate credit is given and the new creations are licensed under the identical terms



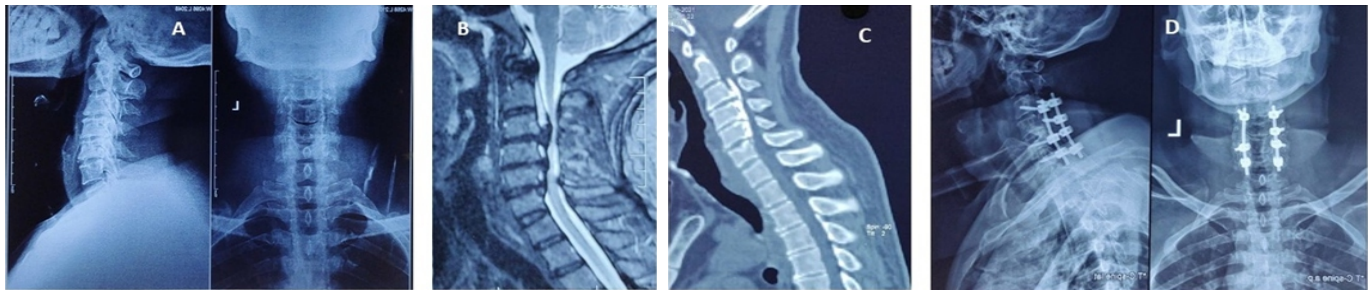


Figure 1: X-ray showing a faint opacity abutting the spinal canal suggesting of ossified posterior longitudinal ligament (a). the MRI showing discontinuous band like low signal intensity structure along the posterior border from C2 till C6 in T1 sequence and hyperintensity signal in T2 sequence abutting the ventral cord surface (b); CT revealed a double line sign with a cortical density over the posterior longitudinal ligament, confirming the diagnosis of OPLL (c); post-operative X-ray showed satisfactory screw placement and adequate laminectomy (d).

Case Report

OPLL is a common cause of cervical spinal cord compression in Asian countries. Continuous A 48-year-old male presented with difficulty in walking and clumsiness of both hands for a 1-year duration. The disease was insidious and progressive, making him unemployed through ambulatory. There were upper motor neuron signs such as increased muscle tone, exaggerated reflexes (upper and lower limb but jaw jerk was absent), a positive Hoffman sign, plantar extensors, and a motor power of 4/5 grade. On a functional score, he was 4/6 on the modified Nurick scale and 11/18 on the modified Japanese Orthopaedic Association (major) scale. An X-ray showed increased bony densities along the sub-axial region's posterior border and degenerative changes (Fig. 1a). The MRI reported a discontinuous band-like low signal intensity structure along the posterior border from C2 till C6 in the T1 sequence and hyperintensity signal in the T2 sequence abutting the ventral cord surface, suggesting OPLL causing cord compression (Fig. 1b). A computed tomography revealed a double line sign with a cortical density over the posterior longitudinal ligament, confirming the diagnosis of the long segment, mixed type of OPLL (Fig. 1c). The patient was operated on with posterior decompression C3-C6 undercutting the C2 lamina. Instrumentation was done with lateral mass screws C3-C6 and rods were carefully secured to the screws, and autologous bone grafts were placed laterally. A gelatin sponge (abgel) corresponding to the laminectomy defect's size was placed in

the midline, and the wound was closed with a drain. Postoperatively, he felt some "lightness" in his limbs and regained his pre-operative power. The immediate X-ray showed satisfactory screw placement and adequate laminectomy (Fig. 1d). However, by 48 h of surgery, there was gradual and progressive deterioration in the muscle power of all extremities (1-2/5). There were no associated fever, headache, and nuchal rigidity episodes. An urgent repeat MRI was done which showed an en-mass heterogeneous signal at the laminectomy site compressing the spinal cord (Fig. 2a, 2b). The patient was wheeled into the operating theater for re-exploration. The gel foam was found swollen and removed piece-meal, and the hematoma was evacuated (Fig. 2c and d). After achieving proper hemostasis and irrigating the surgical site with copious saline, the wound was closed with a drain. The patient started to show improvement immediately postoperatively, and by 3 weeks was able to walk with support. At 3 months, follow-up was complete ambulatory unaided, with an mJOA score improved to 14.

Discussion

Neurological deterioration in a patient following is a medical emergency that needs immediate radiological assessment. Although it can be attributed to various causes, malposition of screws, loss of fixation, retained osseous fragments, or fluid collections are the common causes that need to be ruled out if the surgical procedure was uneventful. On rare occasions,

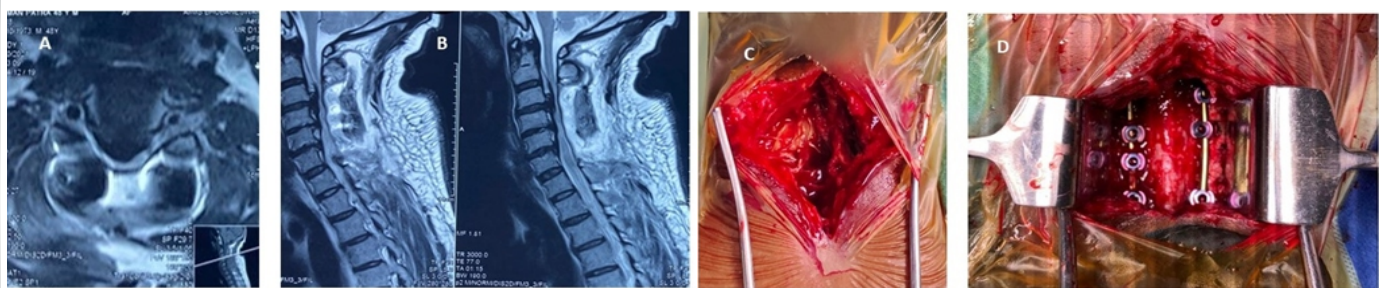

Figure 2: Axial and sagittal post-operative MRI images show a large heterogeneous area overlying the resected posterior elements causing spinal cord compression (a and b); intraoperative images before and after removal of the hematoma (c and d).

gelatin foams have been implicated in causing “mass effect” and compression. Gelatin foams have been commonly used in complex neurosurgical and spine surgeries for more than 75 years [7]. These hemostatic agents control the bleeding and, more importantly, prevent adhesion between the neural elements and the other soft tissues [8]. It is also inert and biodegradable (by the 5th week) [8, 9]. The mechanism of action is by forming an artificial blood clot when it comes in contact with the bleeding surfaces. This passive mode of action builds a mechanical matrix that can provide the tamponade effect within the confined space. The response can be seen as late as by post-operative day 13 [2].

Dubin et al. showed that in patients with early-onset clinical deterioration after the index spine surgery and the MRI evidence of mass on the laminectomy site due to the hematoma organized with the absorbable gelatin sponge, thus causing the cord compression [6]. Friedman et al. reported that the unusual occurrence of post-operative cauda equina syndrome (CES) after 13 days of decompression surgery for lumbar canal stenosis due to a large gel foam at the laminectomy site [2]. Bessette et al. have also reported CES development postoperatively, secondary to retained gel foam pieces in a microdiscectomy patient [4]. Interestingly, Kitahara et al. reported a case of recurrent myelopathy following 6 months of cervical laminectomy [10]. The authors noticed a membrane-like structure at the laminectomy site around the exogenous surgical materials which was used during the index surgery. Herndon and colleagues described a case of gel foam-induced Brown Sequard syndrome after a week of trans-thoracic surgery for congenital kyphosis due to wedged D5 vertebra [3]. Librianto et al. reported a regained neurological outcome after the revision surgery secondary to gel foam-induced early onset cord compression following the deformity correction index surgery for thoracolumbar scoliosis [5]. Buchowski et al. had an unusual

case of epidural spinal cord compression following the usage of gelatin sponges in the cannulated pedicles. The authors observed unabsorbed gelatin sponges in the canal despite the lack of any medial pedicle breach during revision surgery [11].

Friedmann et al. recommend that using only small pieces should it be necessary to use and remove them once hemostasis is achieved [2]. They advocate against using a single large piece, especially in a closed space. The sponges are squeezed to expel any trapped air bubbles before use. Nowadays, a thrombin-gelatin hemostatic matrix is commercially available and used to control bleeding in complex spine surgery [12]. Recently, in-vivo and in-vitro studies showed that the free fat transplantation at the laminectomy decreases the adhesion and the scar tissue formation to exogenous hemostatic agents [13].

Conclusion

When used as a large piece in an enclosed space, Gelatin sponges can cause mass effects and be disastrous for a post-operative patient. While the hardware-related causes are easily diagnosed, this rare etiology is preventable if proper precautions are undertaken.

Clinical Message

A better understanding of the different etiologies of the early-onset post-operative neurological deterioration (specifically after posterior decompression) helps the surgeon for framing a plan of immediate interventions. The gel foam is the most commonly used hemostatic agent in spine surgeries, they are particularly essential in OPLL cases to control the bleeding. The immediate evacuation of the swollen gel foam which lodged and compresses the cord has to be done to regain the deteriorated neurological functions.

Declaration of patient consent: The authors certify that they have obtained all appropriate patient consent forms. In the form, the patient has given the consent for his/ her images and other clinical information to be reported in the journal. The patient understands that his/ her names and initials will not be published and due efforts will be made to conceal their identity, but an anonymity cannot be guaranteed.

Conflict of interest: Nil **Source of support:** None

References

1. Lee SE, Chung CK, Jahng TA, Kim HJ. Long-term outcome of laminectomy for cervical ossification of the posterior longitudinal ligament. *J Neurosurg Spine* 2013;18:465-71.
2. Friedman J, Whitecloud TS 3rd. Lumbar cauda equina syndrome associated with the use of gelfoam: Case report. *Spine (Phila Pa 1976)* 2001;26:2000-2.
3. Herndon JH, Grillo HC, Riseborough EJ, Rich JC. Compression of the brain and spinal cord following use of gelfoam. *Arch Surg* 1972;104:107.
4. Bessette MC, Mesfin A. Cauda equina syndrome caused by retained hemostatic agents. *J Clin Neurosci* 2015;22:1518-20.
5. Librianto D, Fachrisal, Saleh I. Gelatin sponge as a rare and forgotten cause of early-onset neurological deficit post osteotomy of thoracolumbar kyphosis a case report and review of literature. *Int J Surg Case Rep* 2020;75:497-503.
6. Dubin LM, Quencer RM, Green BA. A mimicker of a postoperative spinal mass: Gelfoam in a laminectomy site. *AJNR Am J Neuroradiol* 1988;9:217-8.
7. Abbott WD, Coleman FC. The use of gelatin sponge in neurosurgery. *J Am Med Assoc* 1946;132:329-30.
8. Sabel M, Stummer W. The use of local agents: Surgicel and surgifoam. *Eur Spine J* 2004;13:2-3.

9. Özer A, Köstü B. Use of gelatin sponge affects postoperative morbidity in cesarean section patients. *Med Sci Monit* 2017;23:1141-5.
10. Kitahara T, Hanakita J, Takahashi T. Postlaminectomy membrane with dynamic spinal cord compression disclosed with computed tomographic myelography: A case report and literature review. *Spinal Cord Ser Cases* 2017;3:2-3.
11. Buchowski JM, Bridwell KH, Lenke LG, Good CR. Epidural spinal cord compression with neurologic deficit associated with intrapedicular application of hemostatic gelatin matrix during pedicle screw insertion. *Spine (Phila Pa 1976)* 2009;34:E473-7.
12. Gazzeri R, De Bonis C, Galarza M. Use of a thrombin-gelatin hemostatic matrix (Surgiflo) in spinal surgery. *Surg Technol Int* 2014;25:280-5.
13. Kiviluoto O. Use of free fat transplants to prevent epidural scar formation: An experimental study. *Acta Orthop Scand* 1976;47:3-75.

Conflict of Interest: Nil

Source of Support: Nil

Consent: The authors confirm that informed consent was obtained from the patient for publication of this case report

How to Cite this Article

Nallakumarasamy A, Jain M, Panigrahi S, Sahoo A, Naik S. Gelatin Sponge-induced Early Onset Quadriplegia After the Posterior Decompression for Cervical Myelopathy Due to Ossification of a Posterior Longitudinal Ligament - A Case Report. *Journal of Orthopaedic Case Reports* 2022 June;12(6):70-73.